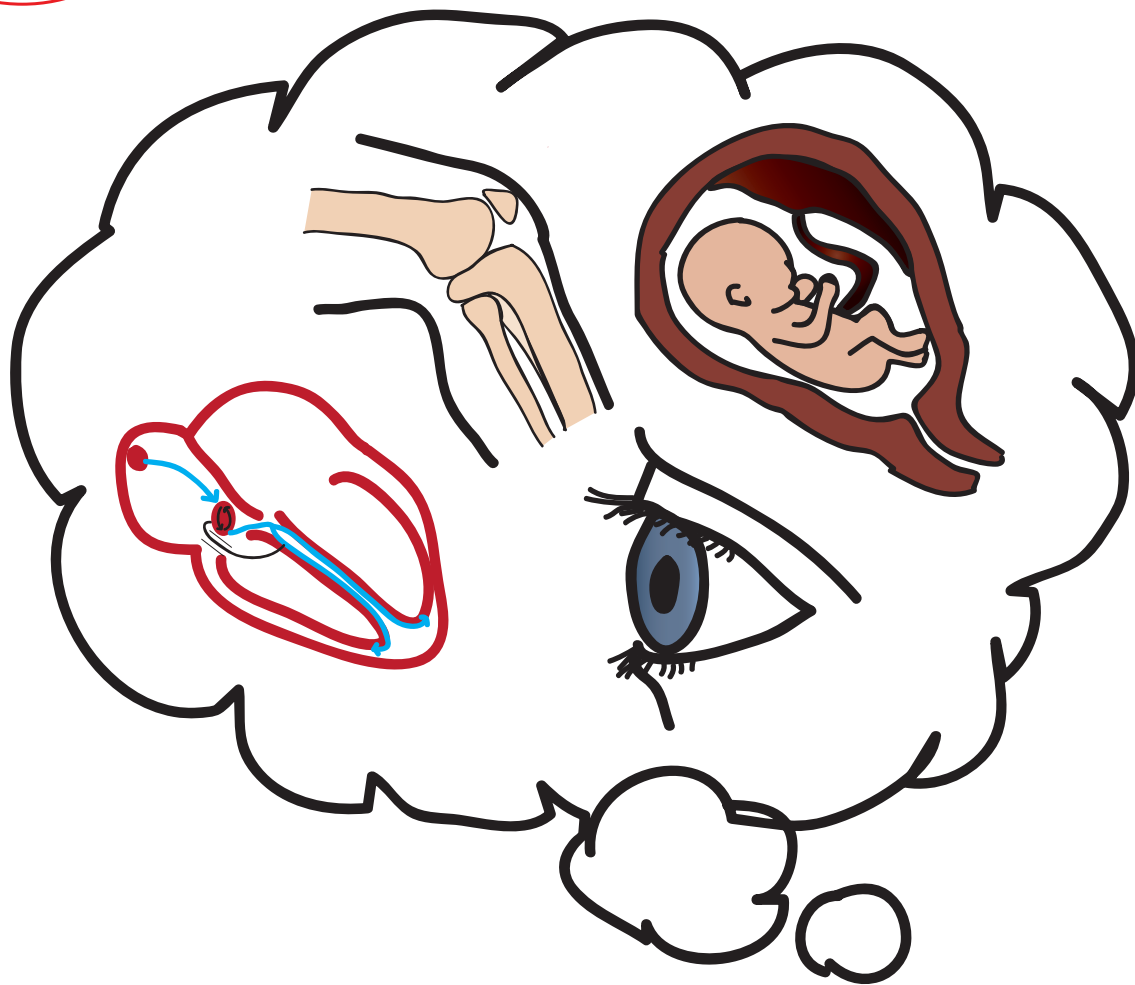




ANNALS OF B POD

Since 1970 - Leadership - Excellence - Opportunity

VOLUME IX, ISSUE I
FALL ISSUE 2015



#AllInADaysWork

also available at tamingthesru.com

2	Physician Lifestyle	Axelson
3	Skin and Soft Tissue Infections	Philpott
4	Neonatal SVT	Winders
6	Postpartum Preeclampsia	Grosso
8	Mastering MC: Tonopen	Ostro
10	Endocarditis	Gorder
15	Knee Pain	Grosso
Back Cover	EKG Focus: Wellen's	Lagasse

#allinadayswork

Sometimes an issue's theme is evident from the beginning- a well planned coordination of cases and perspectives that delivers a set message. Other times, an issue's theme develops itself over the course of publishing the issue- a common thread manifests itself to us as editors as the issue comes together. Every so often, as was the case with this issue, AOBP ends up like a B-pod shift itself- a glimpse of the vast and varied pathophysiology that can present to us as Emergency Physicians at any point.

Some may see the potential to treat neonatal SVT, postpartum preeclampsia, and endocarditis all in one shift as stressful, but not us. We live for the opportunities to treat this range of pathology; to counsel the parent of a sick infant, to save someone's eyesight by diagnosing increased intraocular pressure, or to send an asymptomatic Wellen's to the cath lab for a life saving intervention. This issue is dedicated to all of those shifts in B-pod that leave you in awe of the range of human conditions you see and affect #allinadayswork.

EDITORS

RYAN LAFOLLETTE, MD
BENJAMIN OSTRO, MD
RILEY GROSSO, MD
GRACE LAGASSE, MD

FACULTY EDITORS

WILLIAM KNIGHT, MD
NATALIE KREITZER, MD
ROBBIE PAULSEN, MD

EDITORS EMERITUS

AARON BERNARD, MD
CHRISTOPHER MILLER, MD

Now you know...

Physician Lifestyle and Emergency Medicine:

BY THE NUMBERS

Daniel Axelson, MD
University of Cincinnati R3

As a group, which physician specialty do you think is most likely to have tried marijuana in their lifetime? Emergency Medicine.

As a group, which physician specialty reports the second highest rate of satisfaction with their financial compensation?

Yep, Emergency Medicine. Most satisfied with their financial compensation? Dermatology. #notshocking.

This year's Medscape Physician Compensation and Lifestyle Survey is full of specialty-specific lifestyle information, and it's worthwhile knowing where your specialty shakes out.

While not perfect, the Medscape survey does provide a rare cross-specialty glimpse into physician attitudes and lifestyles. The data was obtained in a voluntary survey format, with approximately 19,500 physicians across 26 different medical specialties providing their self-reported information. Raw numbers of survey respondents varied across specialties, and tended to reflect the number of practitioners nationwide within each specialty.

According to data gathered through March of 2015, physician compensation nationally averages \$195,000 for primary care providers, and \$284,000 for specialists. Emergency Medicine falls in the top half of specialties overall, averaging \$306,000 in salary. We enjoyed a 15% growth in compensation over the past year. With the 10th highest compensation package of the 26 specialties surveyed, EM is only 1% point behind Derm in overall satisfaction with their compensation. A

full 60% of EM physicians feel they are fairly compensated. Contrast this with our orthopedic friends, who, despite being the highest compensated group of physicians are tied at the bottom for 4th most dissatisfied specialty with their compensation. There is no data in this survey on debt accrued prior to residency, however.

Coming in right behind Critical Care, 52% of EM physicians report being burned out. Yes, sadly more than half of us report a loss of enthusiasm for our work, feelings of cynicism, or a low sense of personal accomplishment in our jobs. But interestingly, the severity of EM physician burnout ranks right in the middle of the pack of the 26 surveyed specialties. Could it be that, despite the many challenges to our practice environment, EM attracts a type of personality more readily able to combat burnout and keep its intensity at bay?

As a group, we physicians tend to be socially liberal and fiscally conservative. We overwhelmingly hold religious or spiritual beliefs. We are frustrated by increasing bureaucratic requirements. We draw greatest satisfaction by relationships with our patients. In EM, 1/3 of us are female. 68% of us would choose to go in to medicine if we had to do it all over again. Only 42% of us would choose EM again.

Some other highlights are below. For further reading, check out: Medscape Physician Compensation Report 2015 or Medscape Physician Lifestyle Report 2015

<http://www.medscape.com/features/slideshow/compensation/2015/public/overview> Accessed 8/30/15
<http://www.medscape.com/features/slideshow/lifestyle/2015/public/overview> Accessed 8/30/15

If they had to do it again they would..

	Overall Career Satisfaction	Satisfied w/ income	Choose Medicine	Choose Specialty
1	Dermatology	Dermatology	Family Med	Dermatology
2	Psychiatry	Pathology	Rheum	Ortho
3	Pathology	Psychiatry	Internal Medicine	Cardiology
4	Emergency Medicine	Anesthesia	Critical Care	Plastics Ophtho
5	Pediatrics	Pediatrics	Pulmonary	Gastroenterology
6	Emergency Medicine	Emergency Medicine	Emergency Medicine	Emergency Medicine

Management of Skin and Soft Tissue Infections in the Emergency Department:

Carri Philpott, PharmD
University of Cincinnati

When to use Vancomycin.

Skin and soft tissue infections (SSTI) encompass any infection associated with dermal tissue, including cutaneous abscesses with or without extensive disease, non-purulent cellulitis, and complicated skin infections including those associated with wounds or deep tissue.¹ The most common organisms associated with SSTIs are *Staphylococcus aureus* (*S. aureus*) and *Streptococcus* species.¹ Of these organisms, methicillin-resistant *S. aureus* (MRSA) is increasing in prevalence and must be considered in the treatment of SSTIs in patients that have characteristics of MRSA (see Table 1).² The emergency department is often tasked with the selection and initiation of antibiotic therapy, which is important both for successful treatment of the infection and preventing antimicrobial resistance. Both oral and intravenous antibiotics play an important role in the treatment of SSTIs, and the Infectious Disease Society of America (IDSA) provides recommendations to assist with antibiotic selection (Table 1).²

Identifying patients who are candidates for outpatient CA-MRSA treatment can be difficult in the emergency department. A single-center, retrospective cohort study conducted in an urban, academic, tertiary care institution followed adult patients who received intravenous vancomycin in the emergency department and were then discharged.³ 68% received only one dose of vancomycin before discharge and only 9% of patients met appropriate criteria for vancomycin use based on the 2011 IDSA guidelines (defined as complicated SSTI, bacteremia, infective endocarditis, pneumonia, osteomyelitis, septic arthritis, meningitis, intracranial abscesses).³ Of note, 70% of patients included had a SSTI, highlighting the challenge of selecting initial antibiotics for treatment of this infection in emergency departments.³ Short-term intravenous vancomycin should be

avoided because it provides suboptimal antimicrobial effects and can contribute to the development of drug resistance.³ To minimize incidence of one-time vancomycin use in the emergency department, intravenous vancomycin therapy should be initiated after there is a plan to admit the patient.

Vancomycin is a glycopeptide antibiotic that prevents bacterial cell wall formation.⁴ According to the 2014 Clinical Laboratory and Standards Institute (CLSI), vancomycin MICs against *Staphylococcus aureus* are classified as sensitive at <2, intermediate at 4-8, and resistant at >16.5. There is evidence to suggest that MICs of

1-2 may be less responsive to vancomycin therapy, and there are reports of vancomycin failure with MICs of 2 despite technically being susceptible.⁴ The ideal pharmacodynamic target for optimal vancomycin effectiveness is an AUC/MIC ratio of >400 for organisms with an MIC of 1.⁴ Trough concentrations greater than 15 mg/L have been shown to correlate with this and should be targeted.⁴ Adequate trough concentrations are important not only for optimal antibacterial effects, but also because evidence suggests that troughs of less than 10 mg/L can lead to strains of vancomycin-intermediate *S. aureus* (VISA) with higher MICs.⁴

Continued on page 13

Infection	Symptoms	Treatment
Community-acquired MRSA (CA-MRSA)	<ul style="list-style-type: none"> • Purulent cellulitis • Abscess 	<ul style="list-style-type: none"> • Incision and drainage (I&D) • Oral antibiotics (<i>severe, cellulitis, comorbidities, immunosuppression, extremes in age, septic phlebitis, lack of response to source control</i>) <ul style="list-style-type: none"> • Clindamycin • Trimethoprim-sulfamethoxazole • Tetracycline (doxycycline, minocycline) • Linezolid
B-hemolytic streptococci	<ul style="list-style-type: none"> • Non-purulent cellulitis 	<ul style="list-style-type: none"> • B-lactam (<i>add to trimethoprim-sulfamethoxazole or tetracycline for concomitant MRSA</i>) • Clindamycin • Linezolid
Complicated SSTI	<ul style="list-style-type: none"> • Deep tissue • Surgical/traumatic wounds • Major abscesses • Ulcers • Burns 	<ul style="list-style-type: none"> • Hospital admission for intravenous therapy <ul style="list-style-type: none"> • Vancomycin (perhaps most common) • Linezolid • Daptomycin • Clindamycin • Telavancin

Table 1: Treatment of SSTI based on the 2011 IDSA Guidelines for treatment of MRSA²

Baby, You Make My Heart Race

A Case of Neonatal SVT

Tyler Winders, MD
University of Cincinnati R3

History of Present Illness

The patient is a 3 week old male with no past medical history who presents with increased fussiness. His mother states the patient has simply not been acting like himself. He had an uncomplicated birth and was born at term via Cesarean Section. He was taken home on hospital day 1 without issues, but in the last 24 hours, he has been quite fussy. His mother became concerned when he was unable to take his bottle today. The child has been refusing to eat and has been increasingly difficult to console. He has also had less wet diapers than normal today. Mom has not noticed cyanosis during feeding, recent illnesses or fevers. She also denies the presence of emesis, diarrhea, rashes, congestion, or cough.

The patient has no past medical or surgical history, he is bottle fed, no medications, no known allergies, he lives at home with his parents and does not attend day-care. His siblings are healthy, immunized, and take no medications.

Physical Exam

T 37 HR 275 RR 30 BP 95/54 O2 Sat 100%

Gen- crying on infant warmer, fussy
HEENT- normocephalic, atraumatic, soft anterior fontanelle, tympanic membranes clear bilaterally
Cardiac- tachycardic but regular, no m/r/g, no JVD, strong central pulses
Pulm- symmetric chest rise without accessory muscle use, no stridor, CTAB
Abd- normal scaphoid appearance, soft, non-distended, non-tender diffusely, no appreciated organomegaly
Skin- no rashes, normal turgor, capillary refill <3 seconds
Extremities- warm and well-perfused, no acrocyanosis

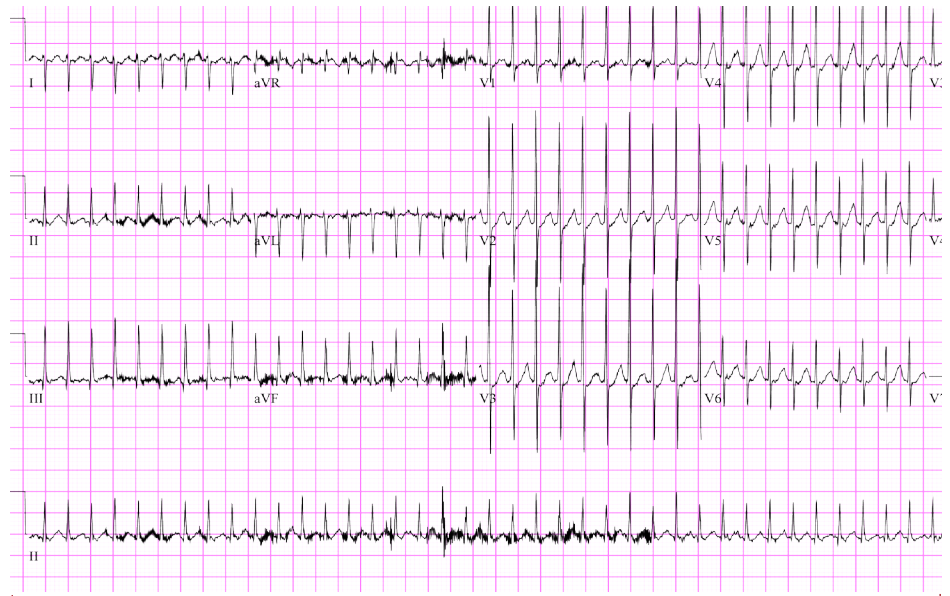

Figure 1: The patient's EKG which shows a narrow complex, regular tachycardia consistent with supraventricular tachycardia

Hospital Course

The patient presented with a heart rate of 275 but was warm and well perfused with strong central pulses and brisk capillary refill. EKG was obtained and consistent with supraventricular tachycardia (SVT) (Figure 1). Pedi-pads were placed just in case the patient decompensated and became unstable. However, the patient remained hemodynamically stable, and therefore vagal maneuvers were attempted first. The patient converted to normal sinus rhythm within 5 seconds of ice application to his face. He ate well and was back to his baseline mental status soon after his cardioversion. The patient was admitted to cardiology where echocardiogram was performed and was unremarkable. The patient remained in normal sinus rhythm throughout his hospital stay. The patient was discharged to follow up with cardiology as an outpatient, and was not prescribed any anti-arrhythmic agents.

Discussion

Supraventricular tachycardia is the most common arrhythmia in children. SVT most often affects children with normal hearts, although structural abnormalities and critical illness are considered risk factors. The 2 most common mechanisms of SVT are atrioventricular reentrant tachycardia (AVRT) and atrioventricular nodal reentrant tachycardia (AVNRT). One electrophysiology study of 139 patients found AVRT to account for 73% of cases and AVNRT to account for 13% of cases.² To help simplify the pathophysiology, one can think of both AVRT and AVNRT are subsets of reentrant tachycardia propagated by slow and fast conduction pathways that devolve into a circular, malignant rhythm (See "Rhythm Breakdown" on Page 11). The locale of the reentrant pathway is what differs between the two. AVRT involves an extranodal accessory pathway, while AVNRT involves slow and fast pathways in the AV node itself. Of note, this definition classifies Wolff-Parkinson-White Syndrome into the AVRT category.

With patients presenting in SVT, it is important to begin with the basic PALS algorithms and immediately differentiate stable versus unstable. If the patient is unstable, simply remember **2 joules per kilogram synced cardioversion**. If the patient is stable, recognize there are multiple treatment options available. As far as recognizing the unstable infant, look for evidence of heart failure, significant pallor, or decreased level of consciousness in addition to simply checking a blood pressure. If the patient requires cardioversion, PALS recommends 0.5-2.0 J/Kg delivered synchronously. Pediatric pads are preferred, but adult pads are an option if no pediatric pads are readily available.

Our patient fell into the stable, narrow-complex tachycardia algorithm. It is important to keep in mind that wide complex tachycardia often has significantly different underlying pathology than narrow complex and should be treated as such. The cutoff for a wide complex tachycardia in pediatrics is a QRS > 0.09 seconds.⁴ Since our patient was in narrow complex tachycardia, we elected to trial vagal maneuvers prior to initiating pharmacologic interventions. The preferred vagal maneuver in infants is the diving reflex. The infant should be placed in a sitting position, and a bag of ice should be placed on the infant's face while simultaneously laying the infant back quickly. A second option is rectal stimulation using

a thermometer. The concept behind both is to elicit a strong vagal response in a patient unable to voluntarily valsalva. One retrospective study found vagal maneuvers to be successful in 63% of SVT in children.³

If vagal maneuvers fail, adenosine is considered the drug of choice as it is a short acting but quite powerful AV nodal blocking agent that interrupts the reentrant conduction pathways causing the arrhythmia.⁴ The recommended dosage in pediatrics is 0.1 mg/kg. If this is not successful, providers may reattempt with 0.2 mg/kg (max of 6mg and 12mg respectively). Other medications to consider would be amiodarone (5mg/kg over 20-60 minutes) or procainamide (15mg/kg over 30-60 minutes), but both of these medications may cause hypotension and involvement of a pediatric cardiologist prior to initiation may be advisable.

1. Colluci R, Silver M, et al. "Common Types of Supraventricular Tachycardia: Diagnosis and Management." - American Family Physician. N.p., Oct. 2010. Web. 21 July 2015.
2. Garson A, Gillette PC, McNamara DG. Supraventricular tachycardia in children: clinical features, response to treatment, and long-term follow-up in 217 patients. J Pediatr. 1981;98(6):875-82.
3. Kugler JD, Danford DA. Management of infants, children, and adolescents with paroxysmal supraventricular tachycardia. J Pediatr. 1996;129(3):324-38.
4. Spencer B, Chacko J, Sallee D. The 2010 American Heart Association guidelines for cardiopulmonary resuscitation and emergency cardiac care: an overview of the changes to pediatric basic and advanced life support. Crit Care Nurs Clin North Am. 2011;23(2):303-10.

Expert Opinion

Special Thanks to CCHMC PEM Faculty Dr. Brad Sobolewski and CCHMC Pediatric Cardiology Faculty Dr. Chris Statile & Dr. Peace Madueme for their assistance with this article.

The following is a question/answer session with Dr. Statile on pediatric SVT.

Check out PEMcincinnati.com/blog for this article and more great pediatric emergency medicine info.

AOBP: Anecdotally, if ice to the face does not work in the stable infant in SVT, have you had success with continued efforts at vagal maneuvers (for example: augmenting cooling with the moro reflex) or do you move on to pharmacologic therapy quickly?

Dr. Statile, Pediatric Cardiologist, CC-MHC: I would continue to try vagal maneuvers while stable. Often, these maneuvers are not done appropriately and others may work. After ~15 min of being unsuccessful, medical therapy is appropriate but taking into consideration how long the patient is perceived to have been in tachycardia (a person in tachycardia all day should be converted faster).

AOBP: Discussing pharmacologic cardioversion. There is a decent amount of evidence for Verapamil, but it seems like adenosine is the preferred drug in the ED. What is your experience, if any, with verapamil?

Dr. Statile: Verapamil is a higher class drug and warrants more experience. We don't use it much (except our EP colleagues) and has a longer half life. As such, we use it as a tertiary medication and would never use it

in the ED on a stable patient. If the patient is stable and cannot be converted using adenosine in the ED we would recommend cardiology consultation and likely transfer to the cardiac ICU for further treatment. We recommend getting cardiology involved earlier, rather than later.

AOBP: We've tried vagal maneuvers and adenosine without success and now are considering a third line agent such as amiodarone, procainamide, and digoxin. What is your preferred third-line agent for cardioversion in the stable neonate in SVT once vagal maneuvers and adenosine have failed?

Dr. Statile: This question is not so straightforward. It depends on whether there has been transient response with resumption of tachycardia or no response at all. For the former, often times the circulating catecholamines need to be decreased (which can be accomplished with beta blockers and sedation), as they are the reason for continuing to re-enter into tachycardia, before a repeat attempt. For the latter, it may not be SVT after all. In either case, cardiology should be made aware because at this stage as this no longer qualifies as simple SVT.

AOBP: At what point would you consider synchronized cardioversion for a stable neonate in SVT?

Dr. Statile: Only if there are IV issues or medication issues. In the stable infant, this usually is not necessary if it is true SVT. We would rarely use synchronized cardioversion for a stable neonate in re-entrant SVT. However if the infant was in atrial flutter, synchronized electrical cardioversion may be necessary. Again this should not be done without input and involvement of a cardiologist as long as the patient is stable. If the patient is unstable, then of course electrical cardioversion is indicated.

AOBP: When is it appropriate to consult pediatric cardiology in these cases? Does every stable patient that undergoes successful cardioversion in the ED require inpatient cardiology consultation? Are any of these patient's safe for outpatient follow up?

Dr. Statile: All patients with SVT that are cardioverted (medically, vagally, or electrically) deserve a consultation in the ED by the cardiology fellow. Whether the patient needs to be

Continued on page 13

Shortness of Breath:

Riley Grosso MD
University of Cincinnati R3

A Case of Postpartum Preeclampsia

History of Present Illness

The patient is a 29 year old female G3P2102, post-operative day 8 from an uncomplicated repeat low transverse cesarean section at 39 weeks gestation after an uncomplicated pregnancy, who presents with SOB. She was discharged home on post-operative day 2 with a healthy female infant. She returns today with complaints of shortness of breath for 3 days and swelling in her bilateral lower extremities for 6 days. Over the same time course she endorses orthopnea, paroxysmal nocturnal dyspnea, weight gain, and chest pain. She describes the chest pain as substernal and intermittent. She also feels as if her chest is making a crackling noise when she exhales. She denies fevers, cough, nausea, vomiting, headache, or abdominal pain. She reports that her incision is healing well. She denies pain or drainage from the incision. She is breast-feeding her daughter, who is doing well at home. She has not yet seen her Obstetrician in follow-up but did receive all appropriate prenatal care.

Past Medical History

Nephrolithiasis, intrauterine fetal demise of twins at 16wks

Past Surgical History

Cesarean section x3, dilation and curettage of the uterus for above intrauterine fetal demise

Social History

Non-smoker, lives with husband and 2 children, occasional EtOH before pregnancy, no drugs

Medications

PNV, Percocet PRN

Allergies

No known

Lab Work-up

WBC 8.8 H/H 11.5/32.6 Plt 337
BMP: 139/4.6/108/22/14/0.54/88
Troponin: 0.09 BNP: 915
Uric acid: 8.0 AST 69 ALT 94
LDH: 276

Hospital Course

The patient presented on postpartum day 8 in mild respiratory distress with edema, hyperreflexia, and hypertension. Her clinical picture was consistent with postpartum severe preeclampsia. She was admitted to labor and delivery and started on IV magnesium. Her edema was treated with Lasix and hypertension was adequately controlled with oral Nifedipine and PRN dosing of Hydralazine for SBP > 160. Given her elevated troponin, BNP, and nonspecific ECG findings, cardiology was consulted to evaluate for peripartum

Physical Exam

T98.8 HR 46 RR 18 BP 164/96 O2 Sat 95%

General - Well appearing, sitting straight up in bed, mildly labored breathing

Eyes - Pupils equal and reactive, extraocular eye movements intact

Mouth - Mucous membranes moist, pharynx normal without lesions

Chest - Mild tachypnea, rales and diminished breath sounds in the bilateral lower lung fields

Heart - S1 and S2 normal, no murmurs, rubs, or gallops, bradycardic with a regular rhythm

Abdomen - Soft, non-tender, non-distended, no masses or organomegaly, incision clean, without discharge or erythema

Neurological - Alert, oriented, normal speech, 1 beat of myoclonus bilaterally, +2 reflexes bilaterally

Musculoskeletal - No joint tenderness

Extremities - Pedal edema +1 bilaterally, intact peripheral pulses

Skin - Normal coloration and turgor

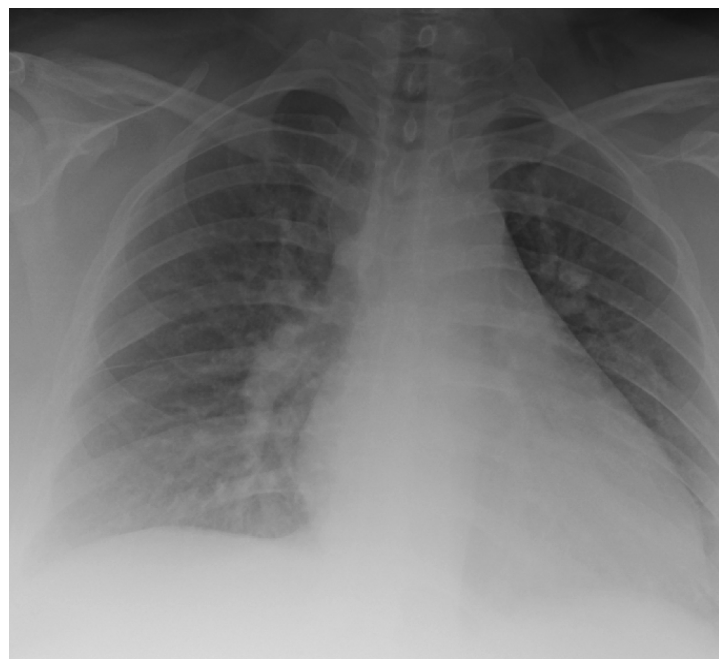


Figure 1: CXR showing bilateral infiltrates concerning for pulmonary edema

cardiomyopathy. Her ECHO was normal and cardiology attributed her elevated troponin to strain from preeclampsia. The patient was weaned off of magnesium after 36 hours. Over the course of her hospital stay, her troponins trended downward and her symptoms improved. She was discharged home without antihypertensives and instructions to follow-up as scheduled with both OB and her primary care physician.

Discussion

Five percent of all pregnancies are complicated by preeclampsia. It is one of four disease processes in pregnancy that are diagnosed based on blood pressure elevation greater than 140/90 after 20 weeks gestation (Figure 2).¹ The presence of severe symptoms in preeclampsia, as described below, drives both the treatment options and timing of delivery.⁷ There are 2 subsets of preeclamptic patients: early onset, which occurs at <34 weeks gestation, and late onset which is seen after 34 weeks gestation and up until 6 weeks postpartum.² Early onset preeclampsia, which accounts for 5-20% of cases, is caused by impaired spiral artery remodeling in the placenta which leads to a release of inflammatory factors.² This inflammatory state and associated sympathetic response leads to a systemic vasoconstriction resulting in the defining feature of preeclampsia: elevated blood pressure.² This systemic vasoconstriction also leads to endothelial dysfunction which results in the proteinuria, soft tissue edema, pulmonary edema, and liver capsule stretch. Late onset preeclampsia, which accounts for 80% of preeclamptic patients, is thought to be a manifestation of the patient's predisposition to cardiovascular dysfunction secondary to the physiologic demands of pregnancy.²

Shortness of breath secondary to pulmonary edema can be present in both preeclampsia and peripartum cardiomyopathy. Therefore, B-natriuretic peptide (BNP) can sometimes help practitioners differentiate between these two disease processes. However, as is evident with our patient, elevated BNP can also be seen in more severe cases of preeclampsia, thus limiting its specificity for postpartum cardiomyopathy. In one study, the median BNP levels in normal patients, mild preeclamptics, and severe preeclamptics were 17.8, 21.1, and 101 pg/mL, respectively.⁵ Given the patient's elevated BNP and troponin, there was a high suspicion for associated cardiomyopathy. Surprisingly, this patient did not have evidence of cardiomyopathy on ECHO.

One in 2,000 pregnant women will suffer from eclampsia, a well defined complication of preeclampsia that manifests as tonic clonic seizures.⁸ Even though the term preeclampsia indicates that its severe features would precede eclamptic seizures, up to one third of patients will have only mild range blood pressures at the time they seize.^{2,8} Even more concerning is that 10% of patients will have proteinuria as their only manifestation of preeclampsia at the time of onset of eclampsia.⁸

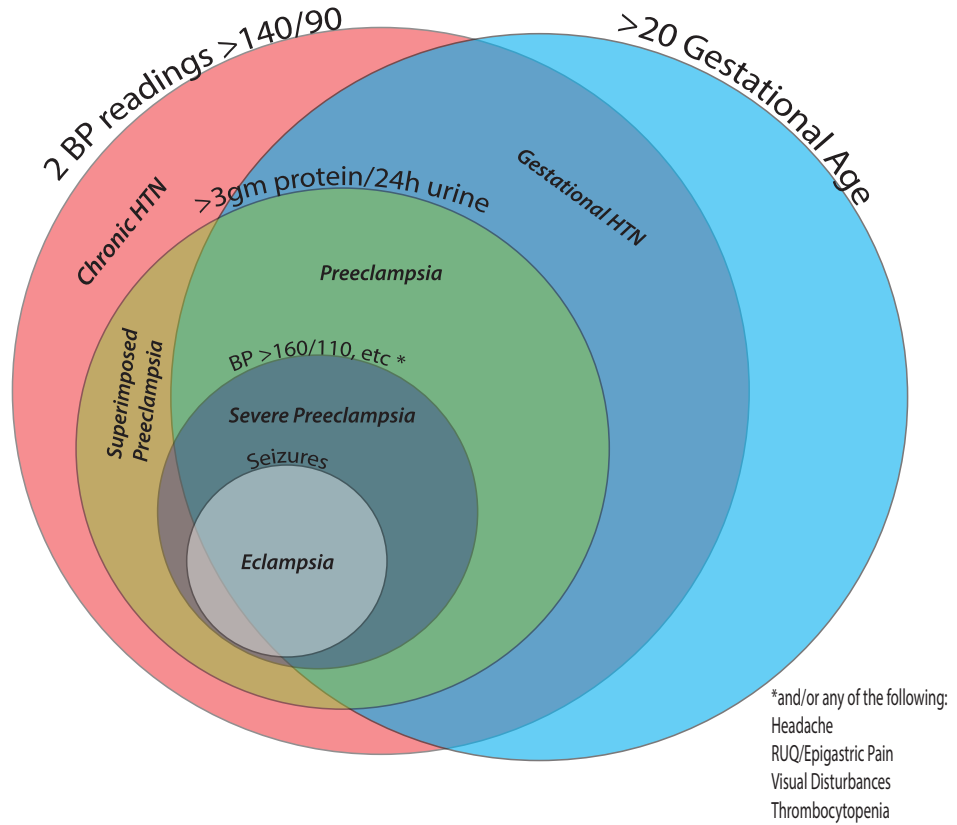


Figure 2: Classifications of Hypertension in Pregnancy (diagram not accurate representation of prevalence)

This argues against the traditional teaching that eclamptic seizures are a form of hypertensive encephalopathy. Rather, this supports the current theory that eclamptic patients seize due to cerebral edema, yet another manifestation of endothelial dysfunction that is responsible for the other symptoms found in severe preeclampsia.^{2,8}

Traditionally, delivery of the placenta is taught to be the definitive treatment for preeclampsia. However, there is a small, but significant, portion of patients who will present with symptoms of preeclampsia postpartum. The most relevant of these to emergency physicians are the patients who present with late postpartum preeclampsia (LPP), which by definition presents greater than 48 hours and less than 6 weeks after delivery.⁴ This population has been discharged from the hospital and are the most likely to present to the emergency department directly, without involvement of the obstetricians prior to arrival. The data on these presentations is limited. However, one study of approximately 50,000 deliveries revealed that 152 (0.3%) women were readmitted to the hospital for LPP.⁴ On average, these women present with symptoms on postpartum day 8, as was the case with our patient.⁴ Our patient's pregnancy was uncomplicated. She did not suffer from pre-ec-

lampsia prior to delivery. Her uncomplicated prenatal course may lead a less experienced practitioner to place LPP lower on their differential. However, in the above study 63.2% of patients readmitted for LPP and 77% readmitted with postpartum eclampsia did not have any antecedent diagnosis of hypertension in pregnancy.⁴

Shortness of breath was our patient's presenting complaint and was the second most common complaint of patients in this study, behind headache.⁴ Risk factors for developing LPP include a BMI greater than 30, maternal age ≥ 40 , latino or black ethnicity, and a new diagnosis of gestational diabetes.⁶

The goal of emergency department care of patients with LPP is two-fold: treatment of hypertension and prevention of eclampsia. The American College of Obstetrics and Gynecology recommends treating severe-range blood pressures of over 160/100 with IV Labetalol or Hydralazine.⁹ As was the case with our patient, repeat doses are often required to achieve this goal.⁹ Severe range blood pressures or mild range blood pressures plus any of the symptoms of severe preeclampsia should prompt treatment with magnesium to prevent eclamptic

Continued on page 15

Mastering Minor Care

Benjamin Ostro, MD
University of Cincinnati R4

This series focuses on expert advice
from our minor care gurus
Drs. Trott and Hooker.


Under Pressure: A Tonopen Tutorial

PREPARE

1. The Tonopen lives in the cabinet in the attending office.
2. Adequate corneal analgesia is key. Instill tetracaine in both eyes prior to using the Tonopen.
3. If you are assessing the patient for corneal abrasions, perform the fluorescein exam prior to using the Tonopen as the Tonopen may inadvertently cause small abrasions.
4. Place a cover over the tip. It slides on like a condom and then roll the ridge into the groove.

CALIBRATE

1. The Tonopen should be calibrated before each and every use.
2. With a cover on the tip of the instrument, hold the instrument in a vertical position with the tip down.
3. Press the on button quickly twice.
4. The display will show CAL.
5. Wait 30-60 seconds until the instrument displays UP.




6. Immediately turn the instrument 180 degrees so that the tip is pointing toward the ceiling.
7. The instrument should display GOOD, and if it does, it is ready for use.



If the instrument displays bAd you must calibrate the device again.

MEASURE IOP

1. Having the patient laying flat or against a headrest facilitates measurement; however, the pressure can be measured in any position.
2. Hold the eyelids open but make sure that you do not put any pressure on the eye.
3. Push the button once and you should see double rows of dashes. Careful not to push twice as it will cause the instrument to go back into calibration mode.



4. Tap gently and quickly on the cornea. You should hear beeps as each measurement is taken. After 4 valid readings are obtained, a final beep will sound and the averaged measurement will appear on the LCD along with the single bar denoting statistical reliability (you want them all to be less than 5% difference or you need to repeat the measurement). You do not (contrary to local urban legend) need to measure three different times. You only need to tap quickly until it gives the final beep. That gives you four valid readings.

TROUBLE SHOOTING

I cannot get the instrument to calibrate and give two rows of dashes. What is wrong!?

If you try repeatedly and cannot get the instrument to calibrate, it may need new batteries. You can replace them yourself, or you can just email Dr. Hooker, and he will fix it as quickly as possible. Batteries should be kept in the same cabinet as the instrument in the attending office.

I'm getting very high measurements, but clinically there is low suspicion for elevated IOP. What's going on?

The most common cause of a falsely elevated reading is that the operator has inadvertently put pressure on the eye. When holding the eye open with your finger and thumb, make sure that there is no pressure being put on the eye. You can always check the other eye. If both are elevated, it is likely operator error.

The instrument calibrates fine, but when I go to measure the IOP, it does not beep.

The instrument must have two rows of dashes (not one) in order for it to take measurements. Make sure that it has two rows of dashes.

I've provided adequate analgesia but the patient is still squinting.

Ask the patient to keep both eyes open during the procedure. If they shut the good eye, they are more likely to squint and reject the Tonopen.

Kari Gorder, MD
University of Cincinnati R2

Altered Mental Status With a New Murmur: A Case of Endocarditis



History of Present Illness

The patient is a 57-year old male with a history of hypertension and coronary artery disease who presented with a chief complaint of altered mental status. The patient's grandson was visiting from out of state and found his grandfather sitting on the couch, unresponsive to physical stimuli with his "eyes rolled back in his head." This episode lasted approximately one minute, and then the patient awoke, but remained confused. He now says he feels better.

The grandson reports that he learned today that the patient had been using heroin. The patient himself was unable to give any history and the grandson had only been in town for the day.

Past Medical History

Hypertension and Diabetes

Medications

Lisinopril, Hydrochlorothiazide,
Metformin

Social History

Daily IV heroin use, occasional EtOH, lives alone,
occasional THC use, smokes 1ppd x 30 years

Physical Exam

T 101.3 HR 115 BP 99/57 RR 27 O2 Sat 99%

Constitutional- He appears well-developed. No distress.
HEENT- Normocephalic and atraumatic. EOM are normal.
Pupils are equal, round, and reactive to light.
Neck- Normal range of motion.
Cardiovascular- Tachycardic rate, regular rhythm, II/VI systolic murmur best appreciated at right upper sternal border, intact distal pulses
Pulmonary/Chest- Effort normal. No respiratory distress. No wheezes.
Abdominal- Soft. Non-tender, Non-distended
Musculoskeletal- He exhibits no tenderness.
Neurological- Moves all extremities spontaneously and symmetrically. Oriented to himself but not to place or time
Skin- Track marks and small petechial hemorrhages on the dorsum of his feet.

Lab Work-up

WBC 12.8 H/H 13/38 Plt 159
BMP: 128/3.4/96/22/11/0.82/115
AST: 92 ALT: 62 Lactate: 4.9

Hospital Course

The patient's presentation was concerning for endocarditis, given his history of IV drug use, fever and new murmur. His EKG was remarkable for sinus tachycardia. Three sets of blood cultures were drawn approximately 15 minutes apart in order to detect intermittent bacteremia. The patient was started on broad-spectrum antibiotics including vancomycin and gentomycin and admitted to the medicine service for treatment of presumed endocarditis.

The patient's blood cultures quickly returned positive for MRSA. A trans-esophageal echo revealed aortic and mitral valve vegetations with severe aortic regurgitation, consistent with a diagnosis of acute infective endocarditis. Since the patient presented with a possible new onset seizure, a head CT was obtained which did not show any acute abnormalities. The patient continued to be altered, even after the normal head CT, so an MRI of the brain was obtained. This revealed multiple small, acute infarcts consistent with septic emboli (Image 1). Despite multiple rounds of IV antibiotics, the patient remained persistently bacteremic. He was not a candidate for cardiac surgery due to his severe malnutrition and drug use. He was transitioned to hospice and died approximately one month after he was diagnosed.

Modified Duke Criteria for Infective Endocarditis

2 MAJOR OR 1 MAJOR AND 3 MINOR OR 5 MINOR

Major Criteria

Positive blood cultures
Evidence of endocardial involvement

Minor Criteria

Predisposing heart condition or IVDU
Fever >100.4 F
Evidence of vascular phenomena
Immunologic phenomena
Microbiologic evidence

Figure 1: Modified Duke Criteria for Diagnosis of Infective Endocarditis.

Discussion

Infective endocarditis, an acute infection of the endocardial surface of the heart, is a serious and often fatal disease process whose incidence is on the rise. The rate of hospital admissions for endocarditis has risen approximately 2.4% each year since the late 1980s, which may be partially attributable to increased detection. Increasing rates could also be due to increased intravenous drug use, greater use of implantable cardiac devices or an aging population, all of which are risk factors for the development of the disease. Male sex, poor dentition, structural heart disease and immunocompromised states such as HIV and diabetes are additional risk factors for the development of endocarditis. The pathogenesis is thought to be due to bacteria seeding a damaged or structurally abnormal cardiac endothelium.

The presentation of patients with acute endocarditis can be varied. Classically, the Duke Criteria are often referenced as having greater than 80% sensitivity and specificity, and are the criteria for official diagnosis. However, they may be less helpful in the Emergency Department, where required major criteria such as positive blood cultures or evidence of endocardial involvement may not be readily evident.

Vague constitutional symptoms are the most common complaint, including fever, chills, anorexia and weight loss. Patients who use IV drugs will often present with cardio-pulmonary complaints such as dyspnea, chest pain and cough, likely due to this population's predilection for tricuspid valve endocarditis. Individuals should be asked about recent surgical procedures, including dental work, and the presence of indwelling prosthetic devices, especially valvular prosthetics. Physical exam may reveal the oft-memorized stigmata of endocarditis, including splinter hemorrhages, Janeway lesions, Roth spots and Osler nodes. However, these are only found in up to 50% of patients. Of these classical physical findings, splinter hemorrhages are the most common but are not very specific. Up to two-thirds of patients with acute infective endocarditis will have a heart murmur; however, if the patient has a known previous heart murmur, only 10-20% of these patients will exhibit a change in their preexisting murmur. Fever is present in over 80% of patients. Some patients will have signs or symptoms of other organ system involvement from embolic events, such as septic pulmonary emboli,

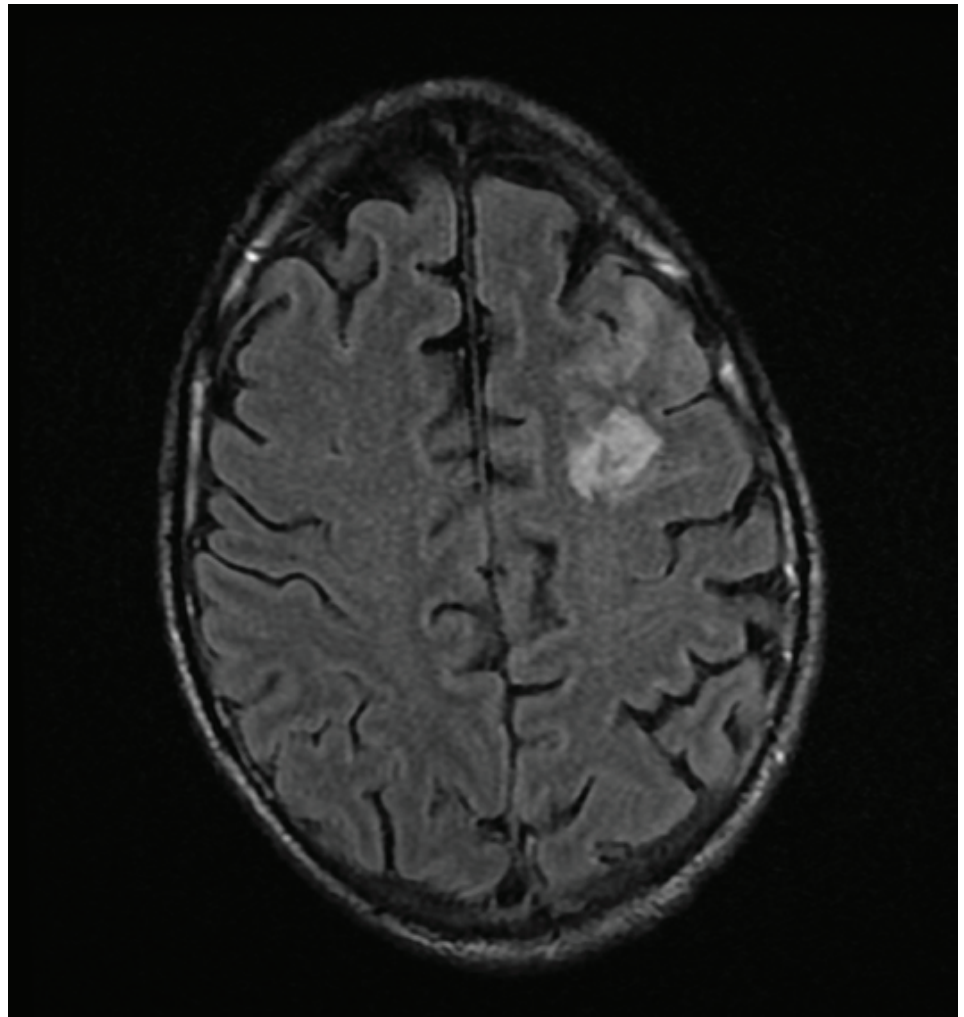


Figure 2: MRI Brain showing acute to subacute infarct in the left front lobe consistent with embolic phenomenon

neurologic deficits or renal infarcts. In rare circumstances, patients can present with acute heart failure due to valve rupture.

Evaluation in the Emergency Department for patients suspected of having acute infective endocarditis includes basic laboratory evaluation, including a renal panel and a CBC, as patients may present with anemia due to RBC destruction or renal failure due to septic infarcts. Inflammatory markers, such as WBC, ESR and CRP, will likely be elevated but are non-specific. A chest x-ray may show evidence of septic pulmonary emboli, but could be clear. Early identification of the causative organism is paramount in the treatment of acute infective endocarditis. Three sets of blood cultures taken from three different sites at least 15 minutes apart, to effectively detect intermittent bacteremia, should be drawn as soon as the diagnosis is suspected and prior to antibiotic administration. Empiric antibiotic therapy is targeted at the most likely causative agent. Streptococci and staphylococci account for greater than

80% of cases of acute infective endocarditis, and as such the classically recommended regimen includes a penicillin-type drug such as augmentin, as well as gentamycin for synergistic coverage. However, given the rise of resistant organisms such as MRSA, vancomycin should be substituted if there is any concern that the patient could be at risk for these pathogens. Formal echocardiography can be ordered in the ED if acute valvular compromise is suspected but should not delay antibiotic administration. Neuroimaging should be obtained if the patient shows signs of altered mental status, as in our patient above. These patients, if candidates, will often require cardiac surgery for definitive management of their disease process.

¹Tleyjeh et al. Temporal trends in infective endocarditis: a population-based study in Olmsted County, Minnesota. *JAMA*. Jun 22, 2005. 293(24): 3022-8.

²Hoehn, B and Duval, X. Infective Endocarditis. *N Engl J Med*. 2014; 368: 1425-22.

³Duval, X et al. Temporal trends in infective endocarditis in the context of prophylaxis guideline modifications: three successive population-based surveys. *J Am Coll Cardiol*. 2012; 59:1968-76.

⁴Murdoch DR et al. Clinical presentation, etiology and outcome of infective endocarditis in the 21st century: the International Collaboration on Endocarditis Prospective Cohort Study. *Arch Intern Med*. Mar 9 2009. 169(5): 463-73

⁵Baddour et al. Infective Endocarditis: Diagnosis, Antimicrobial Therapy and Management of Complications. *Circulation* 2005. 111: e394-e434.

Exploding Cigarettes!

Grace Lagasse, MD
University of Cincinnati R2

History of Present Illness

The patient is a 53 year old male who presents with an oral injury after an explosion of his electronic cigarette. Patient states that he had just replaced the battery in his electronic cigarette when the battery pack exploded immediately after being turned on. He complains that the metal tip of the electronic cigarette is now embedded in his mouth and he thinks that one of his teeth is missing. Patient also complains of pain in his abdomen and in his right hand. He states that he was holding the electronic cigarette in his right hand when it exploded.

Past Medical History

Hepatitis C

Past Surgical History

Neck and shoulder surgery.

Medications

Citalopram, Clonazepam, Ibuprofen, and Oxycodone

Social History

Daily tobacco use

Physical Exam

T 97.6 HR 74 BP 154/92 RR 20 O2 Sat 95%

Constitutional- Awake, alert in no acute distress

HEENT- Noticeable deformity along the left front incisor on the maxilla where there is a foreign body lodged in the gum line. The left incisor cannot be appreciated. Pupils are equal round and reactive to light, extra ocular eye movements are intact, sclera clear, and mucus membranes are moist. There is some singed skin around the border of his mouth. (Figure 2)

Cardiovascular- Regular rate and rhythm, normal S1 and S2. There is no evidence of bruising or discoloration along the anterior chest wall.

Abdomen- Normal bowel sounds. There is a notable area of ecchymosis and a small area of abrasion over the anterior abdominal wall just inferior to the xiphoid process.

Musculoskeletal- Right thumb is tender to palpation, +2 radial pulses bilaterally.

Neurological- Awake, alert and orientated x4. CN 2-12 intact. Normal gait. Sensation intact. Strength is equal and symmetric in the upper and lower extremities.

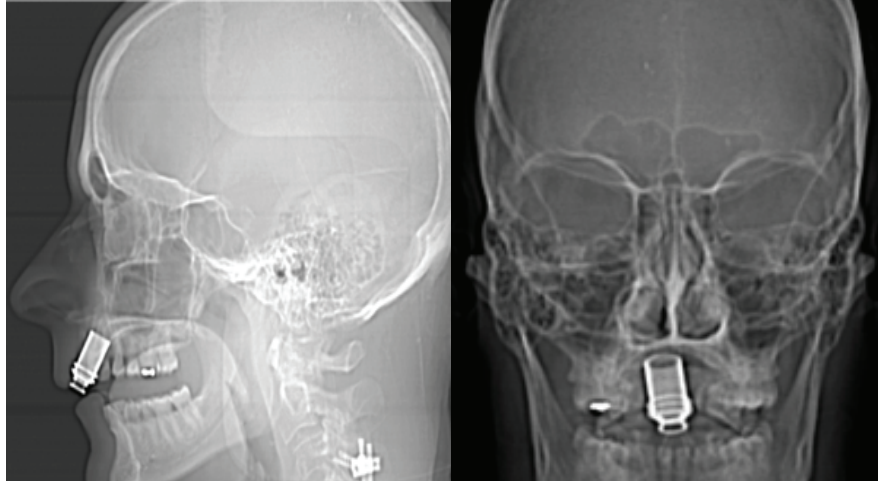


Figure 1: Scout imaging from CT maxillofacial showing metallic foreign body in the anterior midline maxilla.

Hospital Course

Patient had a maxillofacial CT that showed a metallic foreign body in the anterior midline maxilla with associated comminuted fractures of the alveolar ridge (Figure 1). Oral Maxillary and Facial Surgery (OMFS) was consulted. The patient required operative removal of the foreign body by OMFS. Two teeth were extracted as they were found to be nonviable due to the impaction of the foreign body. The patient was also found to have an intra-articular fracture involving the ulnar aspect of the base of the right first proximal phalanx. The patient was seen by orthopedic surgery during his hospital stay, had this injury splinted, and eventually required outpatient surgical repair.

Discussion

Electronic cigarettes (e-cigarettes) create a nicotine-containing aerosol by heating up a solution containing flavoring agents, nicotine, and glycerin or propylene glycol. E-cigarettes were patented by a Chinese pharmacist in the early 2000s and first introduced in the United States in 2007.^{1,2} Awareness and usage of these and other electronic nicotine products has increased since their introduction in 2007. The most recent statistics suggest that approximately 12.3% of the US adult population have used e-cigarettes.^{1,3}

Almost all rechargeable e-cigarette models feature lithium batteries as their power source. Lithium batteries are also commonly found in cellphones and laptops. There are numerous case reports in the literature and news documenting explosions of lithium batteries in cellphones, laptops, and e-cigarettes.^{4,5} Lithium battery explosions are thought to occur through a process known as thermal runaway. Thermal runaway is the result of an exothermic reaction between the components that comprise lithium ion batteries, mainly lithium salt in an organic solvent that allows for efficient transfer of charge through the lithium ions.⁹ In a normal battery, the exothermic reaction creates heat that is dissipated. However, if the heat created in an exothermic reaction is unable to dissipate and leave the system it causes the battery's temperature to rise. This rise in temperature causes an acceleration of the battery's chemical reactions, causing more heat to be produced which acts in a positive feedback loop. This positive feedback loop causes thermal runaway, leading to an explosion much like the one experienced by our patient.⁵

As of August 2015, the Food and Drug Administration (FDA)

Continued on page 14

admitted and watched in the hospital depends a lot on the circumstances surrounding the SVT. If the patient is less than a year of age, most will be admitted for observation. Often (but not always) these patients will be started on an anti-arrhythmic medication. At the very least the parents will have to undergo heart rate monitoring training. The reason for this is that it is often unclear how long the infant was having tachycardia. It is also often hard, if not impossible to tell that they are in SVT without listening or taking a heart rate. These patients also deserve an echocardiogram at diagnosis for the same reason. It is often unclear how long the infant or toddler has been in tachycardia and while SVT is well tolerated for short periods of time up to a few hours, if in it for longer (multiple hours to days) they can develop marked ventricular dysfunction and can get quite sick. Older children that can convey that their heart is beating fast can usually be discharged from the ED with cardiology

follow up after a cardiologist has looked at the tracings and maybe even seen the kid in the while in the ED.

AOBP: The under 12 month olds are concerning, especially given their higher baseline heart rates and the difficulty assessing tachycardia at home. How long is typically “too long” before ventricular dysfunction sets in permanently -ie is there a threshold (if known would likely be retrospective data) after which ventricular function should be assessed? Do symptoms on history correlate with this?

Dr. Statile: Dysfunction usually takes at least 12-24 hours of SVT. It typically recovers pretty quickly but it’s hard (almost impossible) to know how long an infant was in tach prior to presentation. That’s why they all get echoed.

AOBP: Also, what if an Emergency Medicine resident sees a kid with SVT at an outside facility and vagal maneuvers + ad-

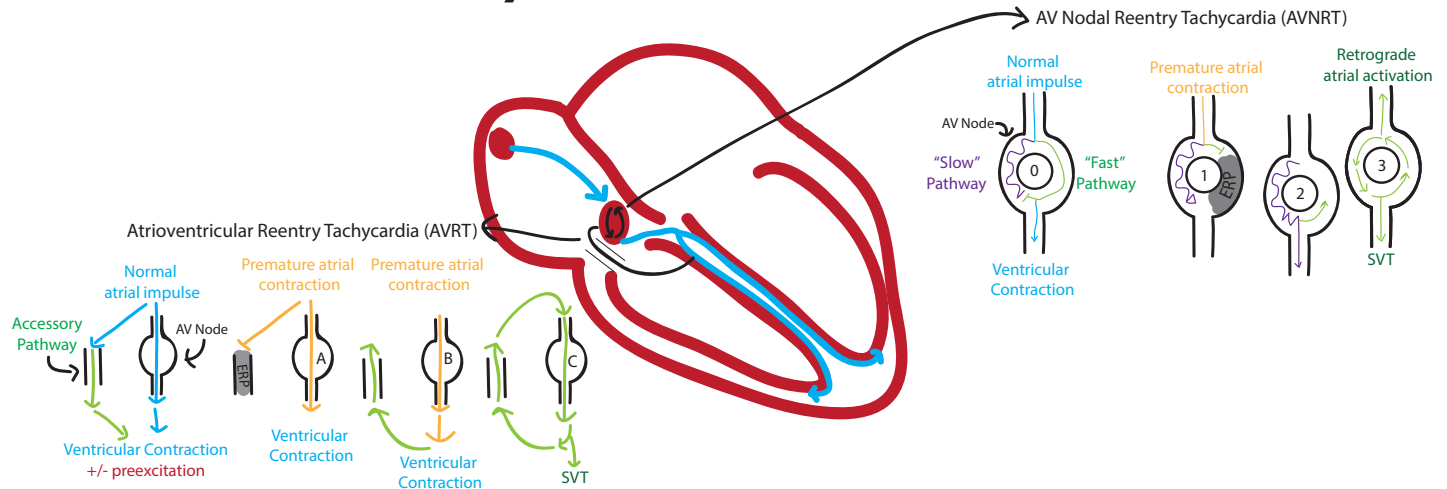
enosine fails? Should they be transferred to the nearest children’s hospital with a cardiologist - or is cardioversion an option if they are >60-90 minutes away from the nearest tertiary center?

Dr. Statile : I would probably double the dose of adenosine and speak to a cardiologist. The reality is that if its not converting with adenosine--- it’s probably not re-entrant SVT and it is something like atrial flutter, congenital junctional ectopic tachycardia or permanent junctional reciprocating tachycardia. I would still get in touch with a cardiologist and have them walk you through what to do next as long as the patient is stable.

AOBP: Is there anything else you want EM physicians to know?

Dr. Statile: SVT in kids is not the same as SVT in Adults. WE WANT TO KNOW ABOUT THE PATIENTS, so get us involved. SVT is much more interesting than that 15 year old girl with chest pain.

Rhythm Breakdown



Atrioventricular Reentry Tachycardia (AVRT)

NSR +/- Preexcitation: The Accessory pathway impulse exits to the ventricles simultaneously or slightly before the AV Node, resulting in NSR from a “hidden” accessory pathway or preexcitation resulting in the sloping up of the PR segment, respectively.

SVT: When there is a premature atrial contraction (PAC), the Accessory pathway is still in its Effective Refractory Period (ERP) from the previous impulse, so the PAC impulse travels down the AV Node (A). By the time the impulse gets through the AV Node, the Accessory pathway is able to conduct retrograde impulses (B) that are closer to the AV Node than the SA node, which leads to the cycle of rapid activation of the ventricles(C).

AV Nodal Reentry Tachycardia (AVNRT)

NSR: The “Fast” pathway exiting to ventricles first and blocks the activation of the ventricle by the “Slow” Pathway (0).

SVT: When there is a premature atrial contraction (PAC), the Fast pathway is still in its Effective Refractory Period (ERP) from the previous impulse, so the PAC impulse travels down the Slow pathway (1). By the time the impulse gets through the AV Node on the Slow pathway, the Fast pathway is able to conduct retrograde impulses (2), which begins the cycle of rapid activation of the ventricles and retrograde atrial activation (3).

Diagram created by: Riley Grosso, MD, University Of Cincinnati Department of Emergency Medicine, for Annals of B-pod 2015
Resources:
1. University of Michigan EKG tutorial; <http://sitemaker.umich.edu/ecgtutorial/avrt/>; accessed July 27th, 2015
2. LITFL EKG Library; <http://lifeinthefastlane.com/ecg-library/svt/>; accessed July 27th, 2015

There is data to support the correlation between vancomycin exposure and vancomycin resistance. Fridkin et al. published a case-control study that identified risk factors for *S. aureus* with reduced vancomycin susceptibility (defined as MIC >4).⁶ There was a statistically significant association between vancomycin use in the past six months and reduced vancomycin susceptibility.⁶ Vancomycin use within the past month had an odds ratio of 13.1 per week of vancomycin use for being associated with a vancomycin MIC of >4.⁶ Furthermore, a second multivariate analysis that looked at more severe MRSA infections and adjusted for known predictors of in-hospital death (age, diabetes, end-stage renal failure) found that both bloodstream infections and MRSA with reduced vancomycin susceptibility were independent predictors of in-hospital mortality.⁶

There was a statistically significant association between vancomycin use in the past six months and reduced vancomycin susceptibility...Both blood stream infections and MRSA with reduced vancomycin susceptibility were independent predictors of in-hospital mortality.

Moise et al. investigated the microbiological effects of prior vancomycin use in patients with *S. aureus* bacteremia.⁷ Of the 81 patients included for bloodstream infections, 38 patients had received vancomycin in the past 30 days.⁷ Of those 38

patients, 37% received vancomycin within the past 7 days and 24% received only a single dose of the antibiotic.⁷ The authors found that vancomycin MICs were significantly higher in patients with recent vancomycin use.⁷ The multivariate analysis found that previous vancomycin use was significantly associated with MICs of 1-2, as opposed to less than 1.⁷ Additionally, there was decreased vancomycin killing in vitro in patients with prior vancomycin exposure.⁷ In conclusion, patients with MRSA bacteremia who received vancomycin in the previous 30 days demonstrated significantly higher vancomycin MICs and reduced vancomycin killing in vitro than MRSA from patients who had not received vancomycin previously.⁷ Of note, 24% of patients who had

received vancomycin in the previous 30 days had only received a single dose of vancomycin.⁷ While not directly studied, the effects that a single dose of vancomycin may have in increasing MRSA resistance is concerning given that this subgroup was a substantial part of the patient population. Based on its mechanism of action, a single dose of vancomycin is unlikely to improve patient outcomes but it may put patients at risk for drug resistant organisms.³ There

are other consequences to the administration of intravenous vancomycin before patient discharge from the emergency department, including delay in the initiation of appropriate oral antibiotic therapy and prolonging the obtainment of therapeutic steady state levels of those agents.³ Furthermore, the opportunity to monitor for both side effects of oral antibiotics and improvement in the SSTI as a result of therapy is lost.³ If patients are being observed in the emergency department before discharge, it is ideal to treat with the antibiotics patients will be discharged on to monitor for both clinical improvement and tolerability of the agents.

- Amin AN, Cerceo EA, Deitelzweig SB, Pile JC, Rosenberg DJ, Serman BM. Hospitalist perspective on the treatment of skin and soft tissue infections. *Mayo Clin Proc.* 2014; 89(10): 1436-1451
- Liu C, Bayer A, Cosgrove SE, Daum RS, Fridkin SK, Gorwitz RJ, Kaplan SL, Karchmer AW, Levine DP, Murray BE, J Rybak M, Talian DA, Chambers HF. Clinical practice guidelines by the infectious diseases society of America for the treatment of methicillin-resistant *Staphylococcus aureus* infections in adults and children. *Clin Infect Dis.* 2011; 52(3): 18-55.
- Mueller K, McCammon C, Skrupny L, Fuller BM. Vancomycin Use in Patients Discharged from the Emergency Department: A Retrospective Observational Cohort Study. *J Emerg Med.* 2015 Mar 20. [Epub ahead of print]
- Rybak M, Lomaestro B, Rotschafer JC, Moellering R, Craig W, Billeter M, Dalovisio JR, Levine DP. Therapeutic monitoring of vancomycin in adult patients: A consensus review of the American Society of Health-System Pharmacists, the Infectious Diseases Society of America, and the Society of Infectious Diseases Pharmacists. *Am J Health Syst Pharm.* 2009; 66(1):82-98.
- Clinical and Laboratory Standards Institute. Performance Standards for Antimicrobial Susceptibility Testing: Twenty-Fourth Informational Supplement. CLSI document M100-S24 (ISBN 1-56238-897-5 [Print]). Clinical Laboratory and Standards Institute, 950 West Valley Road, Suite 2500, Wayne, Pennsylvania 19087 USA, 2014.
- Fridkin SK, Hageman J, McDougal LK, Mohammed J, Jarvis WR, Perl TM, Tenover RC. Epidemiological and Microbiological Characterization of Infections Caused by *Staphylococcus aureus* with Reduced Susceptibility to Vancomycin, United States, 1997-2001. *Clin Infect Dis.* 2003; 36(4): 429-39.
- Moise PA, Smyth DS, El-Fawal N, Robinson DA, Holden PN, Forrest A, Sakoulas G. Microbiological effects of prior vancomycin use in patients with methicillin-resistant *Staphylococcus aureus* bacteremia. *J Antimicrob Chemother.* 2008; 61(1):85-90.

only regulates e-cigarette products that have been marketed for therapeutic purposes, such as smoking cessation. In April of 2014 the FDA submitted, but has not enacted, a "deeming rule" which proposed expanding the FDA's regulatory control to include all electronic tobacco products.⁶ However, in June and July of 2015 the House of Representatives and Senate rejected amendments that would have given the FDA pre-market review of new e-cigarettes and review of e-cigarette products currently on the market.^{7,8} Due to the lack of regulation, significant variability exists between the quality of e-cigarette products. This creates a growing population of consumers vulnerable to the potential for device malfunction and related injuries as highlighted in this case.

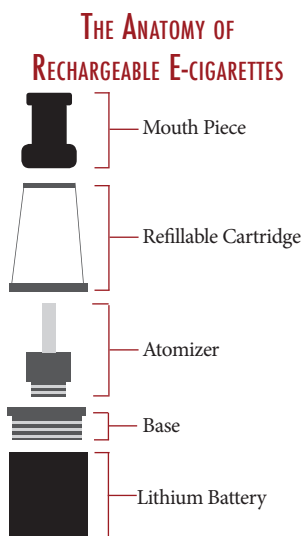


Figure 2. Most rechargeable e-cigarettes have five common components. The mouth piece through which users inhale vaporized nicotine. The refillable cartridge where a solution containing liquid nicotine is stored. The atomizer which commonly uses a heating coil to heat the liquid nicotine into a vapor. The base which connects the atomizer to the energy source, often a lithium battery.

- Regan AK, Promoff G, Dube SR, Arrazola R. Electronic nicotine delivery systems: adult use and awareness of the 'e-cigarette' in the USA. *Tob Control.* 2013 Jan;22(1):19-23. doi: 10.1136/tobaccocontrol-2011-050044. Epub 2011 Oct 27.
- Grana, Rachel, Neal Benowitz, and Stanton A. Glantz. "E-Cigarettes: A Scientific Review." *Circulation* 129.19 (2014): 1972-1986. PMC. Web. 14 Aug. 2015.
- Tobacco Product Use Among Adults - United States, 2012-2013. Centers for Disease Control and Prevention. CDC. 27 June 2014. Web. 14 Aug 2015.
- Yang, Ling et al. "Electronic Cigarettes: Incorporating Human Factors Engineering into Risk Assessments." *Tobacco Control* 23.Suppl 2 (2014): ii47-ii53. PMC. Web. 14 Aug. 2015.
- Qingsong Wang, Ping Ping, Xuejuan Zhao, Guanquan Chu, Jinhua Sun, Chunhua Chen, Thermal runaway caused fire and explosion of lithium ion battery, *Journal of Power Sources*, Volume 208, 15 June 2012, Pages 210-224, ISSN 0378-7753
- "Deeming Tobacco Products To Be Subject to the Federal Food, Drug, and Cosmetic Act, as Amended by the Family Smoking Prevention and Tobacco Control Act; Regulations on the Sale and Distribution of Tobacco Products and Required Warning Statements for Tobacco Products" Federal Register 79 FR 23141 (25 April 2014): 23141 -23207. Docket DA-2014-N-0189. Print
- Wheeler, Lydia. "House Agriculture Bill Takes Aim at FDA E-cig Rules." *The Hill* 19 June 2015. Regulation sec. Web. 14 Aug. 2015. <http://thehill.com/regulation/245536-house-agriculture-spending-bill-takes-aim-at-fda-e-cig-rules>
- Shabad, Rebecca. "Spending Bill Exempts E-cigs from FDA Review." *The Hill* 08 July 2015. Policy sec. Web 14 Aug. 2015. http://thehill.com/policy/finance/247214-gop-rejects-proposal-to-allow-fda-to-regulate-e-cigarettes
- Wenige, Niemann, et al. (30 May 1998). *Liquid Electrolyte Systems for Advanced Lithium Batteries* (PDF). cheric.org; Chemical Engineering Research Information Center (KR). Retrieved 11 June 2010

Case originally seen and referred by Dr. Nicholas Ludmar, MD

An Uncommon Cause of Knee Pain

#quickhit

The Case

The patient is a 28 year old male who presented after injuring his knee while playing soccer. The patient states that while running he felt a pop in his left knee followed by severe pain. On exam, he had an obvious deformity of the lateral aspect of his left knee. His x-ray (Image 1) was read as normal. Given his pain and mechanism of injury, there was concern for fibular head dislocation. A CT was performed that revealed an anterior/inferior subluxation of the fibular head (Image 2, 3). The patient underwent closed reduction, was immobilized and discharged to follow up with orthopedics.

Discussion

Dislocation of the proximal fibular head is an uncommon injury that is often missed on plain x-rays, as was the case in the patient above.¹ The injury usually occurs when force is applied to a slightly flexed knee while the foot is plantar flexed and rotated. Soccer, long jump, parachuting, and snowboarding have all been reported to cause this injury pattern.¹ Anterolateral dislocation is the most common variant of this injury. A subluxation pattern, as seen in our patient, is associated with hypermobile joints and is actually most commonly seen in pre-adolescent females.² This diagnosis is made clinically and should be suspected when there is a lateral knee deformity with pain that is aggravated by ankle movement.¹ CT can make the definitive diagnosis and is often used when clinical suspicion is high with a negative x-ray.¹ Closed reduction of the injury by applying pressure to the fibular head while

Riley Grosso, MD
University of Cincinnati R3

Case originally seen by
Dr. Chris Zammit

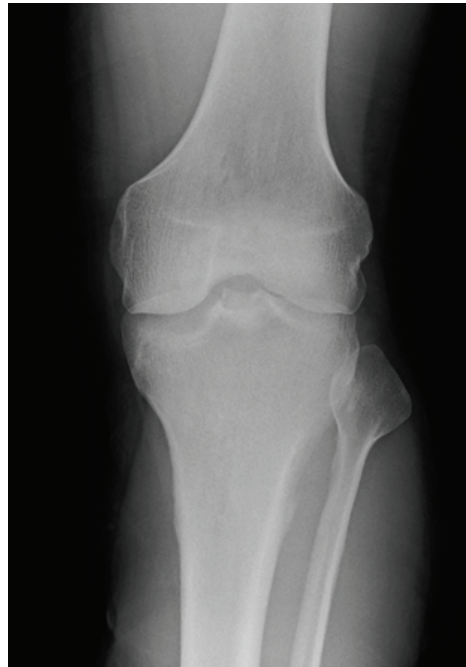

Image 1: No acute traumatic abnormality

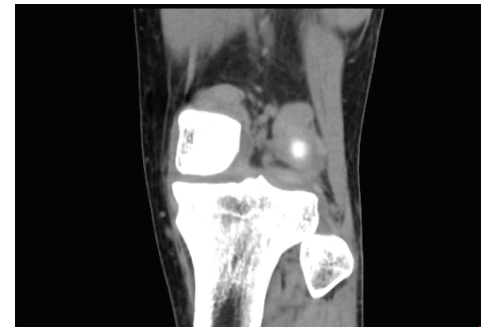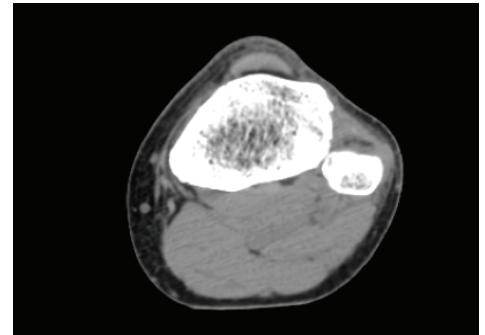


Image 2 & 3: Anterior inferior subluxation of the fibular head.

reversing the injury pattern is the immediate treatment. While closed reduction should be attempted in all cases, post-reduction care is controversial. Practitioners have the option of knee-immobilization or encouraging early mobility as tolerated. There are no definitive studies proving the benefit of one approach over the other. Irrespective of the post-reduction approach, all fibular head dislocation should have orthopedic surgery follow up as

there is a risk for joint hyper-mobility with repeated injury.¹ Neither approach is considered incorrect but all fibular head dislocations should see an orthopedic surgeon as there is risk for hypermobility of the joint if repeatedly injured.

Preeclampsia Continued from page 7

seizures. Emergency physicians should have a low threshold to initiate magnesium, as the number needed to treat for prevention of eclampsia is 90.¹⁰ The most common cause of death in patients with LPP is cerebral hemorrhage secondary to loss of cerebral autoregulation and increased blood pressure.² As such, tight BP control and magnesium therapy are both vital to minimizing morbidity and optimizing survival.² Involvement of our Obstetric colleagues should happen early in the course of these patients treatment, regardless of the severity of disease.

There is mounting data that a diagnosis of preeclampsia is relevant to emergency physicians long after the six week postpartum. These women carry an increased risk of

cardiovascular disease (OR=2.28), cerebrovascular event (OR 1.77), and developing hypertension (RR=3.13) after just one episode of preeclampsia.³ While preeclampsia has often been thought of as an obstetric complaint, patients with LPP and associated vascular disease present to our emergency departments. As such, it is our responsibility as emergency practitioners to be aware of this disease process and be prepared to treat it on every shift.^{4,3}

1. Duhig KE, Shennan AH. Recent advances in the diagnosis and management of pre-eclampsia. *F1000Prime Rep.* 2015 Feb 3;7:24. doi: 10.12703/P7-24.
2. Foo, L., Tay, J., Lees, C. C., McEniery, C. M., & Wilkinson, I. B. (2015). Hypertension in pregnancy: Natural history and treatment options. *Current Hypertension Reports*, 17(5)
3. Brown MC, Best KE, Pearce MS, Waugh J, Robson SC, Bell R. Cardiovascular disease risk in women with pre-eclampsia: systematic review and meta-analysis. *Eur J Epidemiol.* 2013 Jan;28(1):1-19. doi: 10.1007/s10654-013-9762-6. Epub 2013 Feb 9. Review. PubMed PMID: 23397514.
4. Al-Safi, Zain. "Delayed Postpartum Preeclampsia and Eclampsia Demographics, Clinical Course, and Complications". *Obstetrics and gynecology* (New

1. Horan J, Quin G. Proximal tibiofibular dislocation. *Emergency Medicine Journal: EMJ.* 2006;23(5):e33. doi:10.1136/emj.2005.032144.
2. Semonian R, Denlinger R, Duggan R. Proximal Tibiofibular Subluxation Relationship to Lateral Knee Pain: A Review of Proximal Tibiofibular Joint Pathologies. *JOSPT* 1995; 21(5); 248-57

York. 1953) (0029-7844), 118 (5), p. 1102.

5. Resnik, Jamie et al. "Evaluation of BNP levels in normal and preeclamptic women." *American Journal of Obstetrics and Gynecology*, Volume 193, Issue 2
6. Bigelow, Catherine A. "Risk factors for new-onset late postpartum preeclampsia in women without a history of preeclampsia." *AJOG* (0002-9378), 210 (4), p.338.e1.
7. Young, Janet Simmons. "Maternal Emergencies after 20 Weeks of Pregnancy and in the Postpartum Period." *Tintinalli's Emergency Medicine: A Comprehensive Study Guide*. Eds. Judith E. Tintinalli, et al. New York, NY: McGraw-Hill, 2011. n. pag. AccessEmergency Medicine. Web. 1 Jun. 2015. <http://accessemergencymedicine.mhmedical.com/content.aspx?bookid=693&Sectionid=45915435>.
8. Douglas KA, Redman CW. Eclampsia in the United Kingdom. *BMJ* 1994; 309:
9. ACOG Maternal Safety Initiative "Postpartum Preeclampsia Checklist: Emergency Departments" <http://www.acog.org/-/media/Districts/District-II/PDFs/SMI/v2/ED-Postpartum-Preeclampsia-Checklist-Poster-Other-Resources.pdf?dmc=1&ts=20150603T1208255089>
10. Duley L, Gülmezoglu AM, Henderson-Smart DJ, Chou D. Magnesium sulphate and other anticonvulsants for women with pre-eclampsia. *Cochrane Database Syst Rev.* 2010 Nov 10;(11):CD000025. Review. PubMed PMID: 21069663.

Special Thanks to Dr. David McKinney, Maternal Fetal Medicine Fellow in the Department of OBGYN at UCMC for editing and providing material for this article.

Wellens' Syndrome

EKG focus

Grace Lagasse, MD
University of Cincinnati R2

History of Present Illness

The patient is a woman in her 50's with no past medical history who presents with one month of chest pain described as heaviness and dyspnea on exertion that has progressed to chest pain and dyspnea at rest.

Wellens' Syndrome

EKG pattern associated with critical stenosis of the proximal left anterior descending coronary artery. Patients with Wellens' syndrome should not undergo stress testing. Instead, they should go directly to the catheterization lab with cardiology.

Patient Outcome

The patient was taken to the cath lab from the ED for her EKG concern for Wellens' syndrome. She was found to have a 99% lesion in her proximal left anterior descending artery which was treated with a drug eluting stent.

EKG and Case referred by

Justin Benoit, MD and
Robbie Paulsen, MD

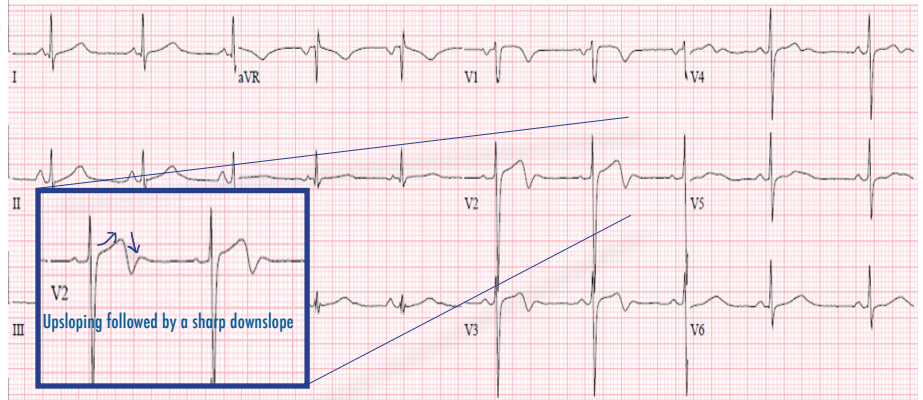
Thank you to Dr. Mel Otten for providing additional EKG examples

¹ Lefebvre C, O'Neill JC, Cline DM. ELECTROCARDIOGRAPHY: NORMAL HEART, ACUTE ISCHEMIA, AND CHRONIC DISEASE. In: Lefebvre C, O'Neill JC, Cline DM. eds. Atlas of Cardiovascular Emergencies. New York, NY: McGraw-Hill; 2015.

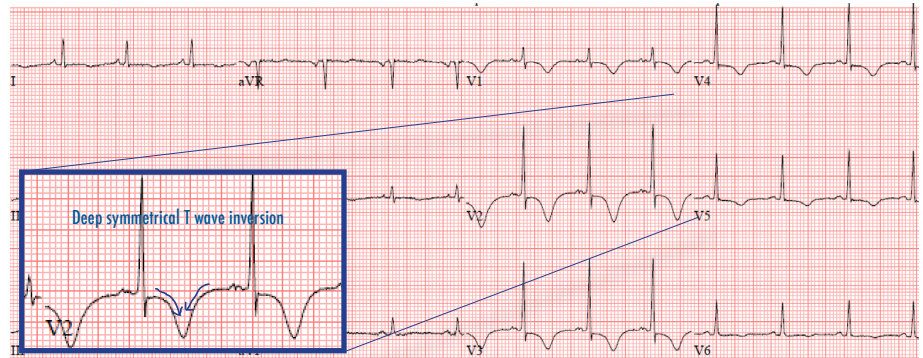
² Parikh, Kishan S., Rajiv Agarwal, Amit K. Mehrotra, and Rajiv S. Swamy. "Wellens Syndrome: A Life-saving Diagnosis." The American Journal of Emergency Medicine. Print

³ Ritchie JV, Juliano ML, Thurman R. Chapter 23. ECG Abnormalities. In: Knoop KJ, Stack LB, Storrow AB, Thurman R. eds. The Atlas of Emergency Medicine, 3e. New York, NY: McGraw-Hill; 2010.

⁴ Singh, B. Y. Singh, V. Singla, and M. C. Nanjappa. "Wellens Syndrome: A Classical Electrocardiographic Sign of Impending Myocardial Infarction." Case Reports (2013). Print.



Type 1 Wellens': Biphasic T waves in leads V2 and V3 characterized by a distinctive upsloping followed by a sharp downslope. This variation of Wellens' syndrome occurs in approximately one quarter of cases.



Type 2 Wellens': Deep symmetrical inversion of T waves in leads V2 and V3. This variation of Wellens' syndrome occurs in approximately three quarters of cases.

EKG Variations of Wellens' Syndrome

1. Biphasic T waves in leads V2 and V3 (Type 1)
2. Deep symmetrical inversion of T waves in leads V2 and V3 (Type 2)

Criteria for Diagnosis of Wellens' Syndrome

1. Prior history of typical chest pain
2. Minimal or no elevation of cardiac enzymes
3. Minimal or no ST segment elevation
4. No pathological precordial Q waves
5. No loss of precordial R wave progression
6. T wave changes consistent with Wellens' syndrome

List of Submitted B Pod Cases

Case

Thyroid Storm
NSTEMI to Cath Lab
Neurosarcoidosis
MRSA Endocarditis
E-Cigarette Explosion
Colonic Obstruction with Pneumatosis
Transverse Myelitis
Ulnar Artery Aneurysm
PE with Pulmonary Infarct
Acute HIV Seroconversion
Fibular Head Subluxation
DRESS secondary to Lamictal
HSV Meningitis

Case Physicians

Ludmer/Stull
Gorder/Redmond
Dailey/Stull
Gorder/Selvam
Ludmer
Ludmer/Walsh
Cousar/Ward
Riddle/Knight
Waters/Latimer
Latimer
Zammit
Schaninger
Ventura/Moellman

Annals of B Pod is looking for YOU to submit your interesting cases of B Pod - There is a composition book at the R4 desk - please make sure to include the R1/R4 involved in the case, a brief synopsis and a patient sticker
annalseditors@gmail.com