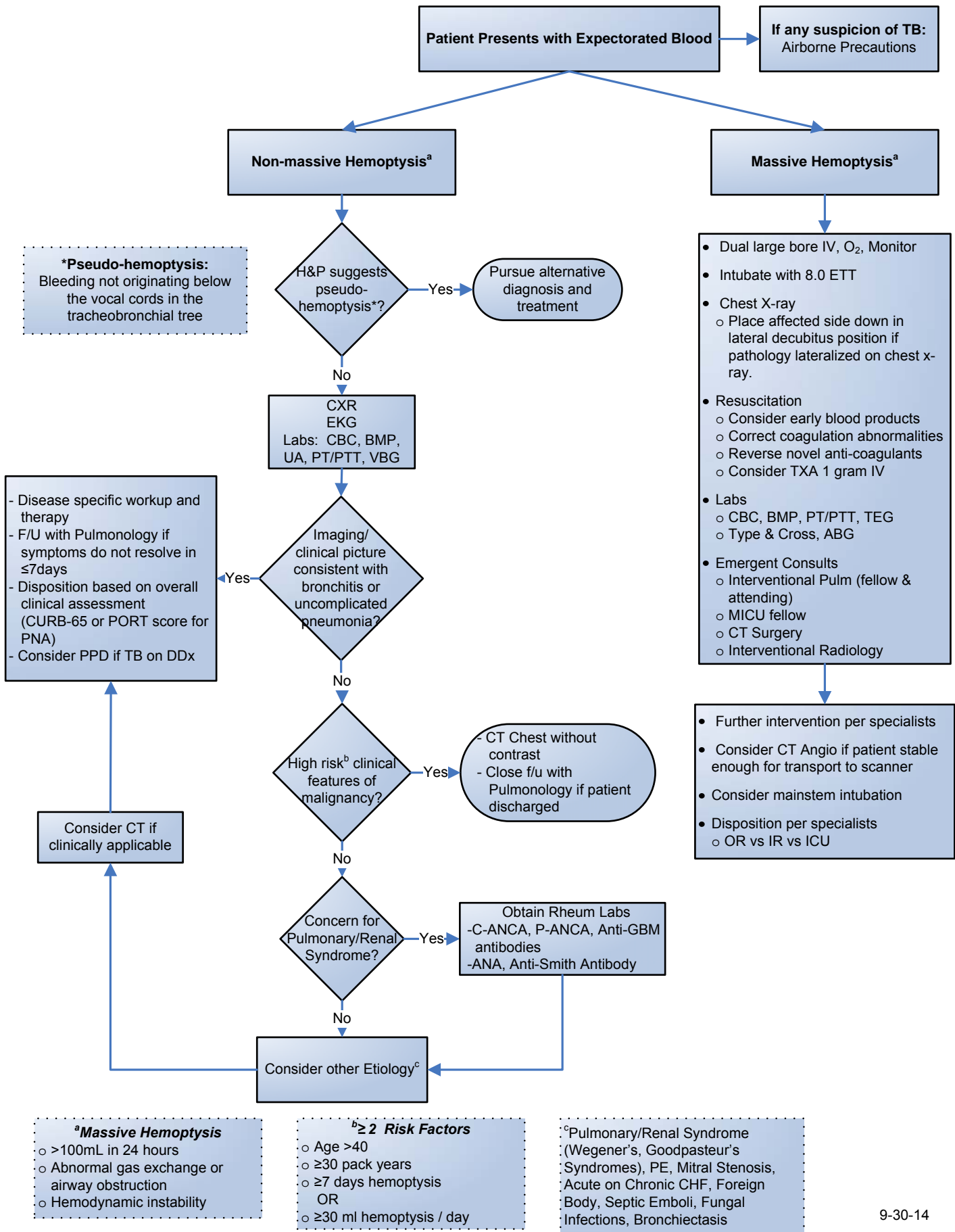


# EmergencyKT: Hemoptysis



## SELECTED REFERENCES

- Aberle DR, et al. "Reduced Lung-Cancer Mortality with Low-Dose Computed Tomographic Screening". *New England Journal of Medicine*, 2011.
- Amirana M, Frater R, Tirschwell P, Janis M, Bloomberg A, State D. An aggressive surgical approach to significant hemoptysis in patients with pulmonary tuberculosis. *Am Rev Respir Dis*. 1968 Feb;97:187-92.
- Bussieres, Jean. "Massive Hemoptysis." *Principles and Practice of Anesthesia for Thoracic Surgery*. New York: Springer, 2011. 485-93
- Chan VL, So LK, Lam JY, Lau KY, Chan CS, Lin AW, Chu CM. Major haemoptysis in Hong Kong: aetiologies, angiographic findings and outcomes of bronchial artery embolisation. *Int J Tuberc Lung Dis*. 2009 Sep;13:1167-73
- Chun JY, Morgan R, Belli AM. Radiological management of hemoptysis: a comprehensive review of diagnostic imaging and bronchial arterial embolization. *Cardiovasc Intervent Radiol*. 2010 Apr;33:240-50.
- Corey R, Hla KM. Major and massive hemoptysis: reassessment of conservative management. *Am J Med Sci*. 1987; 294: 301-309.
- Crocco JA, Rooney JJ, Fankushen DS, DiBenedetto RJ, Lyons HA. Massive hemoptysis. *Arch Intern Med*. 1968 Jun;121:495-8.
- DiLeo, Amedee RG, Butcher RB. "Hemoptysis and pseudo-hemoptysis: the patient expectorating blood." *ENT Journal*. 1995 Dec. Vol 74 pg 822
- Fartoukh M, Khalil A, Louis L, Carette MF, Bazelly B, Cadranel J, Mayaud C, Parrot A. An integrated approach to diagnosis and management of severe haemoptysis in patients admitted to the intensive care unit: a case series from a referral centre. *Respir Res*. 2007 Feb 15;8:11.
- Garzon AA, Gourin A. Surgical management of massive hemoptysis. A ten-year experience. *Ann Surg*. 1978 Mar;187:267-71.
- Haponik EF, Fein A, Chin R. Managing life-threatening hemoptysis: has anything really changed? *Chest*. 2000 Nov;118:1431-5.
- Hirshberg B, Biran I, Glazer M, Kramer MR. Hemoptysis: etiology, evaluation, and outcome in a tertiary referral hospital. *Chest*. 1997 Aug;112:440-4.
- Ibrahim WH. Massive haemoptysis: the definition should be revised. *Eur Respir J*. 2008 Oct;32:1131-2.
- Klein U, Karsai W, Bloos F, et al: Role of fiberoptic bronchoscopy in conjunction with the use of double-lumen tubes for thoracic anesthesia: A prospective study. *Anesthesiology* 1998; 88:346-350
- Knott-Craig CJ, Oostuizen JG, Rossouw G, Joubert JR, Barnard PM. Management and prognosis of massive hemoptysis. Recent experience with 120 patients. *J Thorac Cardiovasc Surg* 1993; 105: 394-397
- McGuinness et al. "Hemoptysis: Prospective High-Resolution CT/Bronchoscopic Correlation" *Chest* 1994.
- Poe RH, Israel RH, Marin MG, Ortiz CR, Dale RC, Wahl GW, Kallay MC, Greenblatt DG. Utility of fiberoptic bronchoscopy in patients with hemoptysis and a nonlocalizing chest roentgenogram. *Chest*. 1988 Jan;93:70-5.
- Prutsky G, Domecq JP, Salazar CA, Accinelli R. Antifibrinolytic therapy to reduce haemoptysis from any cause. *Cochrane Database Syst Rev* 2012;4: CD008711.
- Remy-Jardin M, Bouaziz N, Dumont P, Brillet PY, Bruzzi J, Remy J. Bronchial and nonbronchial systemic arteries at multi-detector row CT angiography: comparison with conventional angiography. *Radiology*. 2004 Dec;233:741-9.
- Revel et al. "Can CT Replace Bronchoscopy in the Detection of the Site and Cause of Bleeding in Patients with Large or Massive Hemoptysis". *AJR*:179, November 2002
- Ruiz W. [Acido tranexamico vs placebo en hemoptisis por TBC pulmonar: estudio piloto double ciego]. PhD Thesis 1994. □
- Sakr L, Dutau H. Massive hemoptysis: an update on the role of bronchoscopy in diagnosis and management. *Respiration*. 2010;80:38-58.
- Shigemura N, Wan IY, Yu SC, Wong RH, Hsin MK, Thung HK, Lee TW, Wan S, Underwood MJ, Yim AP. Multidisciplinary management of life-threatening massive hemoptysis: a 10-year experience. *Ann Thorac Surg*. 2009 Mar;87:849-53.
- Thirumaran M, Sundar R, Sutcliffe IM, Currie DC. Is investigation of patients with haemoptysis and normal chest radiograph justified? *Thorax*. 2009 Oct;64:854-6.
- Tscheikuna J, Chvaychoo B, Naruman C, Maranetra N. Tranexamic acid in patients with hemoptysis. *J Med Assoc Thai* 2002;85:399-404.
- Weaver LJ, Solliday N, Cugell DW. Selection of patients with hemoptysis for fiberoptic bronchoscopy. *Chest*. 1979 Jul;76:7-10.