



# ANNALS OF B Pod

Since 1970 - Leadership - Excellence - Opportunity

VOLUME IX ISSUE IV  
SUMMER ISSUE 2015

1970

#lessonslearned  
CASE SERIES

2015

- 2 **EMTALA** *Axelson*
  - 3 **Know Your avR** *Plash*
  - 4 **Visual Dx: SubQ Air** *Ostro*
  - 5 **Vasopressin** *Welch*
  - 6 **Mastering MC: Cerumen** *Ostro*
  - 7 **#lessonslearned: How to d/c**  
*Stull*
  - 7 **#lessonslearned: Anchoring**  
*Beauchamp*
  - 8 **#lessonslearned: Heretotopic**  
**Pregnancy** *Schaninger*
  - 9 **#lessonslearned: Difficult**  
**Conversations** *Kreitzer*
  - 12 **#lessonslearned: Aortic**  
**Dissection** *Walsh/Benoit*
- Back **EKG Focus: Pericarditis** *Lagasse*  
 Cover

**#lessonslearned**

In July the entire emergency department is full of firsts; firsts shift in B-pod, first solo flights, first successful codes, and first shifts supervising new providers. This is an exciting time -- full of new faces and new roles. July can also be scary. All of those new roles come with uncertainty, fear of the unfamiliar, and immense responsibility.

This issue features cases and #lessonslearned from graduates whose "firsts" were not long ago. These are showcased to serve as a reminder to us all that although this month is full of firsts for the residents, our faculty, nurses, and department have seen many Julys pass and are ready and eager to teach us their own #lessonslearned.

EDITORS

- KRISTOPHER FORD, MD
- RYAN LAFOLLETTE, MD
- BENJAMIN OSTRO, MD
- RILEY GROSSO, MD
- GRACE LAGASSE, MD


FACULTY EDITORS

- WILLIAM KNIGHT, MD
- NATALIE KREITZER, MD
- ROBBIE PAULSEN, MD

EDITORS EMERITUS

- AARON BERNARD, MD
- CHRISTOPHER MILLER, MD

NOW YOU  
 KNOW...  
**EMTALA**



**Dan Axelson, MD**  
**University of Cincinnati R2**

Just four pages in length, it is best known by its acronym: EMTALA. The Emergency Medicine Treatment and Labor Act was codified as law in 1986, and has come to define our specialty with perhaps greater influence than the law has exerted over any other area of medicine. But as oft referenced as EMTALA is within Emergency Medicine, how much do you really know about the law?

Congress passed the EMTALA as part of COBRA, which stands for Consolidated Omnibus Reconciliation Act, which was a bill that addressed multiple different issues facing Medicare at the time. As such, technically speaking EMTALA only applies to hospitals serving Medicare patients, though that currently comprises 98% of all hospitals in the US. EMTALA is only four pages within the larger bill, and initially received little attention. Its purpose, of course, was to prevent the practice of dumping, whereby private hospitals would transfer patients who could not pay for services to public hospitals without regard for their medical condition or clinical stability. Interestingly, at the time of EMTALA's passage, multiple state and national level safeguards against the practice of dumping already existed, and dated back as early as 1946. ACEP even had language in its bylaws prohibiting restriction to medical care based on race, creed, sex, or ability to pay. Enforcement, however, was sparse. Growing reports of dumping in the lay press, and the ever growing (and continued) presence of the federal government in health care ultimately led to the passage of EMTALA.

The law is broken down into nine sections (A-I), the most pertinent of which are the first three. Section A is entitled the Medical Screening Requirement, and mandates that any individual who presents to an emergency department must be afforded an appropriate medical screening examination, including ancillary services deemed to be routinely

available. This applies to everyone, regardless of the acuity of their presenting complaint. Section B is entitled Necessary Stabilizing Treatment for Emergency Medical Conditions and Labor. This section mandates that any patient who presents to a hospital with what is reasonably deemed to be an emergency condition (including active labor) be provided either stabilization of their condition or transfer to a facility that can better serve the patient's needs. Section C, entitled Restricting Transfers Until Individual Stabilized, follows section B mandating that any individual who

“ Its purpose... was to prevent the practice of dumping, whereby private hospitals would transfer patients who could not pay for services to public hospitals without regard for their medical condition or clinical stability. ”

presents to an ED unstable must be stabilized prior to transfer unless: the individual patient requests transfer, a physician has deemed that the benefit of transfer outweighs the risk, or there is no physician available at the facility to care for the patient.

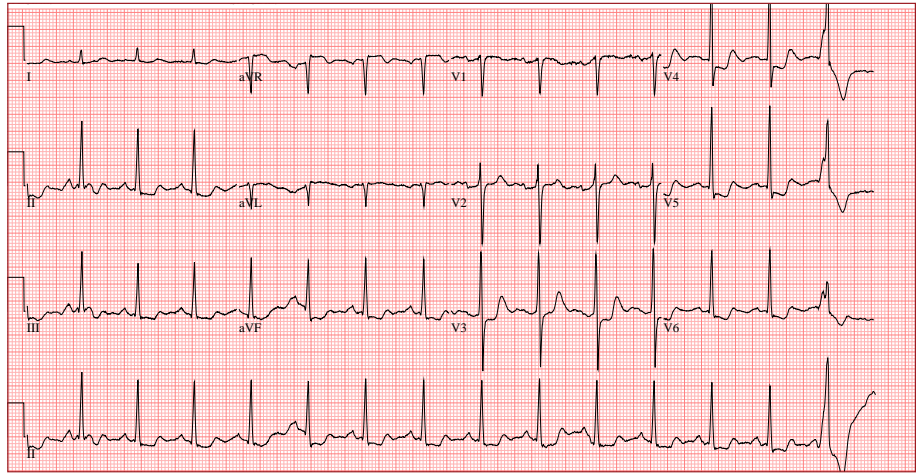
The remainder of the bill deals with enforcement, further subdividing what constitutes "emergency medical conditions" and labor, as well as offering whistle-blower protections to physicians and medical personnel who report EMTALA violations.

While now ubiquitous, the law is not without imperfections. For one thing, many of its descriptions are vague. The first three sections

Continued on page 15

# Respect Your aVR

Walker Plash, MD  
University of Cincinnati RI



Normal sinus rhythm with one PVC. Normal axis. ST elevation in aVR. ST depressions in V3, V4, V5, V6, 2, 3, aVF. No T wave inversions. QRS duration 90 ms. ST segment changes are new compared to prior EKG from a year prior

## History of Present Illness

The patient is a male in his early 80s with history of hypertension, coronary artery disease with three prior stents in 2005, and a subsequent abnormal stress in 2014 presenting for chest pain. The patient reports he has had several weeks of chest pain. The pain is worse with exertion and is associated with exertional shortness of breath. He reports his pain became acutely worse at 5:00 the morning of arrival, two hours prior to

presentation, and has not let up since then. He describes it as a pressure in the center of his chest radiating up into his right shoulder. It is associated with nausea and diaphoresis. The patient denies any tearing sensations or radiation to his back. Nothing makes the pain better or worse. The pain is moderate in severity. No other aggravating or alleviating factors. The patient denies fevers, chills, cough.

## Past Medical History

Hypertension, Previous MI (patient denied), Renal disease, Coronary artery disease with multiple stents placed, Seizure disorder, Gastroesophageal reflux disease and Hyperlipidemia

## Medications

Amlodipine, Aspirin, Atorvastatin, Isosorbide mononitrate, Levetiracetam, Lisinopril, Metoprolol Tartrate, Pantoprazole, Tamsulosin

## Social History

Reports he smokes ¼ pack of cigarettes per day  
Reports he uses marijuana 2-3 times per week  
Denies alcohol use

**Allergies**  
None

## Labs

|                                 |                              |
|---------------------------------|------------------------------|
| Troponin: 0.08                  | Creatinine: 2.87             |
| BNP: 337                        | (normal 0.6-1.3)             |
| Potassium: 3.2 (normal 3.5-5.3) | Glucose: 135 (normal 70-100) |
| CO2: 18 (normal 21-31)          | Hgb: 9.5 (normal 13.2-17.1)  |
| BUN: 27 (normal 7-25)           | Chest XRay - normal          |

|      |            |           |        |        |
|------|------------|-----------|--------|--------|
| Temp | Heart Rate | Resp Rate | BP     | O2 Sat |
| 97.6 | 73         | 18        | 141/49 | 98%    |

## Physical Exam

General: Well-appearing male sitting in bed, appears in no acute distress  
HEENT: Head atraumatic, pupils equal round and reactive to light, extraocular movements intact, sclera clear, mucus membranes moist, oropharynx nonerythematous  
Neck: Supple, no lymphadenopathy  
Pulmonary: Clear to auscultation bilaterally, no wheezes, rhonchi, or rales  
Cardiac: Regular rate and rhythm, normal S1S2, no murmurs, rubs, or gallops, nontender to palpation  
Abdomen: Soft, mildly tender in the epigastrium, nondistended, no rebound and no guarding  
Musculoskeletal: No obvious deformities, no tenderness to palpation  
Vascular: 2+ radial pulses bilaterally  
Skin: Warm, dry, well perfused, no rashes  
Neuro: AAOx4. Sensation intact. Strength grossly equal and symmetric.

## ED + Hospital Course

The patient presented with chest pain, elevated troponin, and new EKG changes. His EKG showed new ST elevation in aVR and diffuse ST depressions in V3, V4, V5, V6, II, III, and aVF. The patient was given aspirin and sublingual nitroglycerin with improvement in his pain. He was started on a heparin drip, and cardiology was called. Based upon his elevation in aVR and elevated troponin, cardiology felt this was a ST-elevation MI and the patient was taken directly to the cardiac catheterization lab. He underwent a left heart catheterization, which showed multivessel coronary artery disease involving the LAD, circumflex, RCA, OMs, and diagonals. He had

a 100% occlusion in his left circumflex which was felt to be the cause of his presentation and significant EKG changes. A stent was placed in his left circumflex and the patient reported improvement in his symptoms post-cath. He also had resolution of his EKG changes and his troponins began to trend down. He was evaluated by cardiothoracic surgery given his multivessel disease, but was felt to be a poor candidate for surgery. He was discharged 4 days after admission on optimal medical therapy.

Continued on page 15

# Vasopressin:

## Use in Advanced Cardiovascular Life Support and Shock States

Patrick Welch, PharmD  
University of Cincinnati

Vasopressin is an endogenous hormone released from the posterior pituitary gland which stimulates multiple vasopressin receptors.<sup>1, 2</sup> Vasopressin receptor physiology guides dosing of exogenous vasopressin in various clinical indications (Table 1). Stimulation of AVPR1a (V1) receptors results in vascular smooth muscle intracellular calcium influx and systemic vasoconstriction. The resultant vasopressor effect is more potent than either norepinephrine or angiotensin II. The vasoconstrictive properties are intensified with increased plasma concentrations.<sup>1, 3</sup> Activation of AVPR2 (V2) causes aquaporin-2 channel insertion into the lumen of the renal collecting duct and thereby increases free water reabsorption and retention.<sup>1, 2</sup> The low-dose vasopressin infusion used in shock states primarily targets the clinical effects of V2 stimulation and exerts relatively moderate stimulation of V1-associated vasoconstriction.<sup>1, 4</sup> Although not primarily targeted for its clinical utility by exogenous vasopressin, stimulation of VAPR1b (V3) causes release of adrenocorticotrophic hormone (ACTH) from the anterior pituitary and is a component of the hypothalamic-pituitary-adrenal axis and stress response.<sup>2</sup>

Vasopressin's potent vasoconstrictive properties are utilized in the management of ACLS.<sup>3</sup> Although a dose-response relationship was identified in animal models, a formal evaluation has not been completed in humans.<sup>3,5</sup> Vasopressin use in refractory ventricular fibrillation and pulseless electrical activity has been associated with greater improvement in coronary perfusion compared to

epinephrine, with no differences in morbidity and mortality.<sup>3</sup> Another study found vasopressin improved survival in asystolic patients compared to epinephrine, theoretically due to vasopressin's ability to maintain potency in the presence of severe acidosis. These subgroup analyses are yet to be confirmed in controlled, prospective trials. A meta-analysis found no difference in outcomes comparing vasopressin to epinephrine.<sup>6</sup> Due to these conflicting results, ACLS guidelines allow one 40 unit dose of intravenous (IV) or intraosseous (IO)

methylprednisolone after the first cycle.<sup>8</sup> Patients also received stress-dose steroids if post-resuscitation shock occurred. The treatment group experienced an increased rate of return of spontaneous circulation and increased survival to hospital discharge with good/moderate cerebral performance score. It is unknown if the combination therapy or individual interventions were responsible for the observed improvement in outcomes in the treatment group. Results of this trial require verification in multicenter studies before the intervention can be implemented broadly.

Within the first six hours of sepsis and septic shock, endogenous vasopressin serum concentrations increase 20-fold to 200-fold compared to baseline.<sup>1</sup>

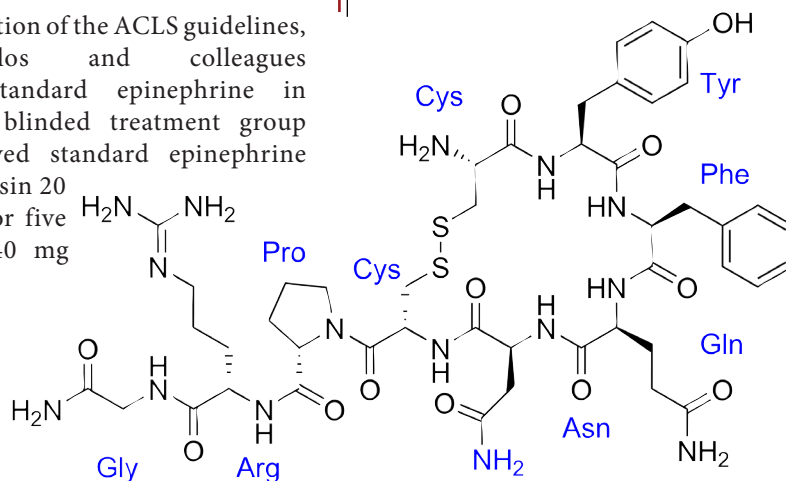
Endogenous vasopressin stores subsequently become depleted, vasopressin synthesis becomes impaired, and serum vasopressin concentrations become inappropriately low. The Vasopressin in Septic Shock Trial (VASST) assessed septic shock patients

| Receptor       | Location                           | Response                | Clinical Target |
|----------------|------------------------------------|-------------------------|-----------------|
| V <sub>1</sub> | Smooth Muscle                      | Vasoconstriction        | ACLS            |
| V <sub>2</sub> | Renal collecting duct              | Free water reabsorption | Shock States    |
| V <sub>3</sub> | Anterior pituitary and hippocampus | ACTH release            |                 |

Table 1: Vasopressin receptors<sup>1,4</sup>

vasopressin in replacement of either the first or second dose of epinephrine in the treatment of cardiac arrest, regardless of the present rhythm (Class IIb, LOE A).<sup>5</sup> If IV or IO access cannot be established, vasopressin 40 units diluted in 5-10 mL sterile water or normal saline may be administered by the endotracheal route (Class IIb, LOE B).<sup>5,7</sup>

Since publication of the ACLS guidelines, Mentzelopoulos and colleagues compared standard epinephrine in ACLS to a blinded treatment group which received standard epinephrine plus vasopressin 20 units/cycle for five cycles and 40 mg



Continued on page 11



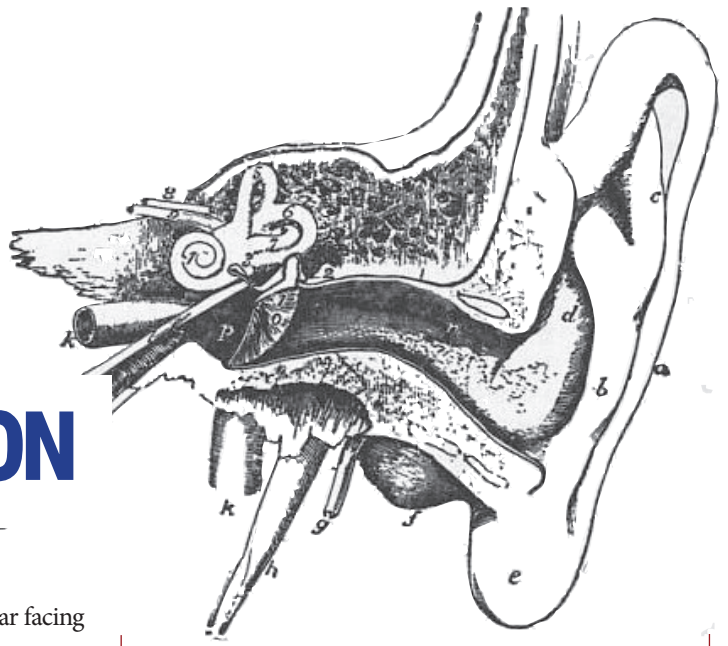
# Mastering Minor Care

Benjamin Ostro, MD  
University of Cincinnati R3

This is the initial installment of Mastering Minor Care. This series will focus on expert advice from our minor care gurus Drs. Trott and Hooker. Enjoy!

## CERUMEN IMPACTION

Wax in - Wax Out



[http://upload.wikimedia.org/wikipedia/commons/b/b6/Britannica\\_Ear\\_1.jpg](http://upload.wikimedia.org/wikipedia/commons/b/b6/Britannica_Ear_1.jpg)

### 1. CERUMENOLYTIC

Positioning is important. Lay the patient supine with the affected ear facing up.

- Fill the ear canal with a ceruminolytic. Although there are several options, Colace and 3% Hydrogen peroxide are the most readily available in our ED

- Fill the canal with the solution and wait 15-30 minutes prior to irrigation

### 2. IRRIGATION

- Fill a 10-20cc syringe with warm water or saline. Warm water will prevent dizziness that cold water induces. Attach a 18 or 16G angiocath to the syringe.

- Insert the angiocath just inside the external canal. Instill the water rapidly and with force.

Current evidence suggests that the use of ceruminolytics may improve irrigation success by as much as 97 percent.<sup>1</sup>

1. Hand C, Harvey I. The effectiveness of topical preparations for the treatment of earwax: a systematic review. Br J Gen Pract. 2004;54:862-7.



Welcome to the UC EM Class of 2019! Looking forward to some great cases...



**Gillian Beauchamp, MD**  
**University of Cincinnati 2014**

*Dr. Beauchamp was a Chief Resident in 2014 and is currently a toxicology fellow at Oregon Health and Science University*

I vividly remember the case of a young man who presented to ED with a report of being ‘found down’ that stands out because it humbled me as a learner and as a physician. I had made the decision to pursue a toxicology fellowship, so I had been reading up on the various toxidromes and taking a deep dive into whatever I could find about designer street drugs. I’d become fascinated by hyperthermia, muscular rigidity, clonus - all findings I hoped to see in a patient with a toxicologic exposure.

This patient was the one I had been waiting to care for.

EMS reported that he’d been using ecstasy and that he was found by friends lying at the bottom of a stairwell at a party. EMS described him as responsive to painful stimuli only. They said he felt ‘very warm’ and gave him fluids and oxygen by non-rebreather mask.

I was excited. This was not your standard abdominal pain or back pain patient. This was tox. Good tox. I examined the patient and noted he was protecting his airway and had bilaterally dilated pupils which were reactive to light. That’s probably his sympathomimetic syndrome, I thought - if this was an anticholinergic patient, his pupils would be dilated but wouldn’t be reactive. He had coarse breath

sounds and normal bowel sounds. His skin was warm and diaphoretic. He had bilateral lower extremity hyperreflexia, 7 or 8 beats of clonus at the ankles, but no muscle rigidity. This was slam dunk serotonin syndrome. I grabbed my medical student and reveled in demonstrating the exam findings. “This is classic serotonin syndrome from ecstasy”, I told him.

I ordered labs, a chest x ray and even decided against ordering a urine drug screen. After all, no good future toxicologist would rely on a urine drug screen as a diagnostic test.

About 20 minutes later I was called to his room for a ‘seizure’. On my exam, the patient was intermittently extensor posturing. He was tachycardic, hypertensive, and remained hyperthermic despite fluid resuscitation and cooling. I called my attending, who had recently finished his Neurocritical care fellowship. I quickly ran through the patient’s history and exam findings, describing his slam dunk serotonin toxidrome. “Look at this clonus”, I said, “classic serotonin syndrome”. “You know what else is classic here?” he said, “the clonus he has from his massive head bleed”. My heart sank. We managed his airway and ran him over to CT.

The patient had a massive intracranial hemorrhage. I felt myself crashing downward from my position at the ‘top of the world’ to a place of humili-

with the patient, the providers caring for her found out she was not being foolish or non-compliant but was concerned with the costs of surgery. The patient had opted to give up her insurances just a few weeks earlier to save money on running the small business she owned with her husband. This decision was made in order to keep the business open. The recovery time needed post-operatively was also a concern to the patient, who needed to be at work with her husband daily to keep the business running. The patient explained that this injury happened while out on her nightly walk, which she takes because her primary care physician told her she needed to exercise more frequently. The patient was told to exercise so she could lose weight, lower her blood pressure and avoid developing diabetes and the costs associated with it.

**#lessonslearned**

ty and self-doubt. We’re taught over and over to form a differential diagnosis. I neglected to do this. I was so impressed with the new knowledge I’d gained from my reading that I dove in, anchoring on a toxicologic diagnosis that was particularly convenient for my area of interest.

I learned to be humble that day; to recognize that every patient needs to be looked at both closely and from a distance. I like to think of the process as ‘zooming out.’ I learned to dive in, find out what the patient is experiencing, but then pull back and look at the patient as if I’m viewing them from far, far away. I had zoomed in and seen a patient with clonus, hyperthermia and hyperreflexia from ecstasy-induced serotonin syndrome. Had I zoomed out, I would have seen a patient with altered mental status and multiple beat clonus, found down at the bottom of a stair well, at very high risk for a traumatic intracranial hemorrhage.

**#lessonslearned**

The art of medicine involves finding a balance between ‘diving in’ and ‘zooming out.’ Sometimes zooming out takes you to places that are difficult, like recognizing that the patient you are about to discharge has nowhere to go, no resources, and not a hope in the world of filling any of the prescriptions you have just written. Sometimes, however, zooming out can save you and your patient from yourself: from your passions, your biases, and from what you read just before your shift.



**Matt Stull, MD**  
**University of Cincinnati 2015**

*Dr. Stull is a recently graduated Chief Resident and is currently starting a Critical Care Fellowship at University of Michigan in Ann Arbor, MI.*

A 54 year-old female comes in with a fall on an outstretched hand after a mechanical trip. She presented to the emergency department with a badly displaced distal radius fracture. The physicians caring for her consulted orthopedic surgery, who told the patient she should be admitted for operative fixation of her distal radius fracture the next day. The patient adamantly refused the admission. Multiple doctors saw her and tried to browbeat her into being admitted, which she continued to refuse. This was initially attributed to noncompliance. However, after a lengthy discussion

**#lessonslearned**

We too often think that because a patient don’t follow our instructions that they are “bad patients” but sometimes that is because we don’t live up to the root of our name, doctor, meaning to teach in Latin. We get frustrated that people don’t follow our instructions when actually we don’t spend the time explaining ourselves or the reason for our instructions. We too often assume that if they don’t take our advice it’s because they don’t recognize our expertise and are irrational or just plain stupid. At the end of the day taking the extra 10 seconds to sit and truly listen to your patient may not just save you time, but could radically change their care.





**Caitlin Schaninger, MD**  
**University of Cincinnati 2014**

*Dr. Schaninger is a former Chief Resident and is currently an attending at UCMC along with completing an operations fellowship.*

# Always Trust the 30

Still trying to talk yourself out of a test at 30 seconds

## History of Present Illness

The patient is a female in her late 20s who presents with abdominal pain and vaginal bleeding. She is currently 7 weeks pregnant based on her last menstrual period. She states that she has had right lower quadrant pain and vaginal bleeding for the past two hours. The patient describes her abdominal pain as sharp and radiating to her right groin. She admits to one episode of emesis. The patient denies diarrhea, dysuria, frequency, hematuria, headache, or dizziness.

This is the patient's fourth pregnancy. Her previous three pregnancies resulted in two full term live births and one premature live birth. All three children are living.

### Past Medical History

Polycystic ovarian syndrome  
 Kidney stones  
 Pre-eclampsia

### Past Surgical History

C-Section x 2

### Labs

UA: 17 RBCs, 58 WBCs, large leukocyte esterase, few bacteria  
 Beta-HCG: 22,579  
 Hgb: 11  
 Wet Prep: Negative

### Medications

Multivitamin

### Allergies

None

|            |        |
|------------|--------|
| Temp       | BP     |
| 97.2       | 141/86 |
| Heart Rate | O2 Sat |
| 97         | 100%   |
| Resp Rate  |        |
| 18         |        |

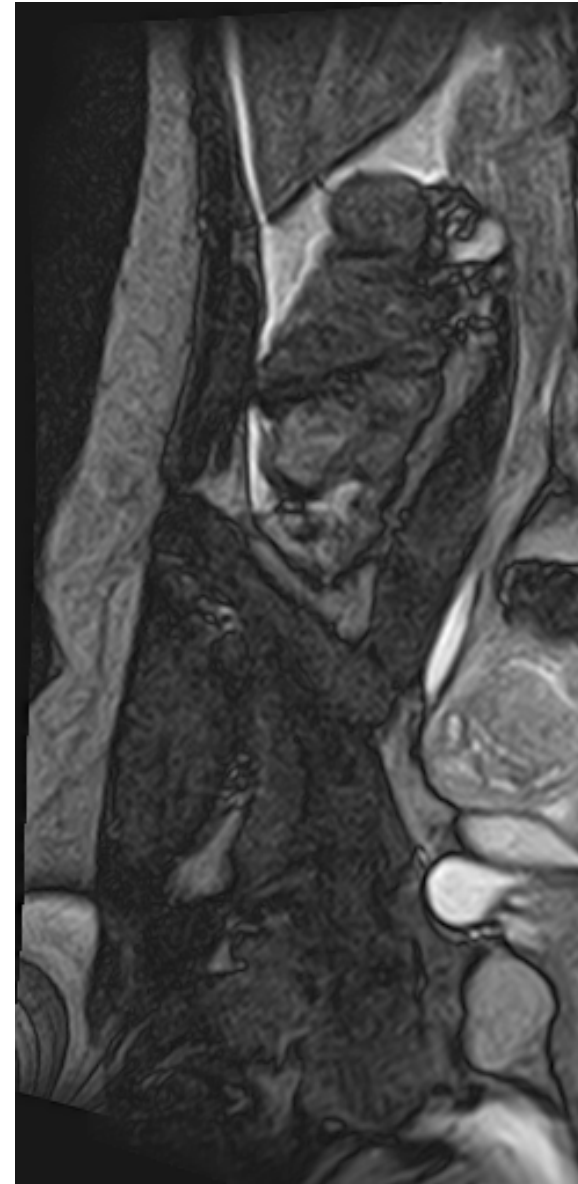
### Physical Exam

General: Alert, appears to be in pain and looks uncomfortable  
 HEENT: Conjunctivae pink, anicteric, mucous membranes moist  
 Neck: Supple with full range of motion  
 Pulmonary: Clear to auscultation bilaterally without wheezing or crackles. Non-labored breathing.  
 Cardiac: Regular rate and rhythm, no appreciable murmurs or rubs.  
 Abdomen: Soft, non-distended. Tender to palpation in the right lower quadrant and right groin with voluntary guarding. No organomegaly or masses.  
 Genital urinary: No costovertebral angle tenderness bilaterally. Normal appearing external female genitalia. A small amount of scant brown discharge is visualized in the posterior fornix. The cervical os is closed. There is no cervical motion tenderness, adnexal fullness or masses. Patient had a tender uterus on bimanual exam that did not lateralize.  
 Musculoskeletal: Moving all extremities spontaneously  
 Skin: Warm and dry  
 Neuro: Alert and conversing appropriately

## ED + Hospital Course

The patient presented with abdominal pain and vaginal bleeding in the setting of pregnancy but without a confirmed intrauterine pregnancy (IUP). She then had a bedside transvaginal ultrasound preformed that showed an IUP as demonstrated by the presence of a yolk sac within a gestational sac. A mild amount of trace free fluid was also noted in the Pouch of Douglas. Threatened abortion was initially considered as the etiology for the patient's symptoms

however serial abdominal exams in the emergency department were significant for increasing point tenderness in the right lower quadrant localizing to McBurney's point. This raised concern for possible appendicitis as an etiology for the patient's symptoms. An MRI of the abdomen and pelvis was preformed which showed a right adnexal mass with free fluid in the pelvis consistent with a ruptured ectopic pregnancy. A formal transvaginal ultrasound was performed



MRI Abdomen - Complex cystic abnormality in the right adnexa suspicious for a ruptured ovarian cyst or a ruptured ectopic pregnancy and extensive complex ascites suggesting possible hemorrhagic ascites. Nonvisualization of the appendix. Appendicitis cannot be excluded.

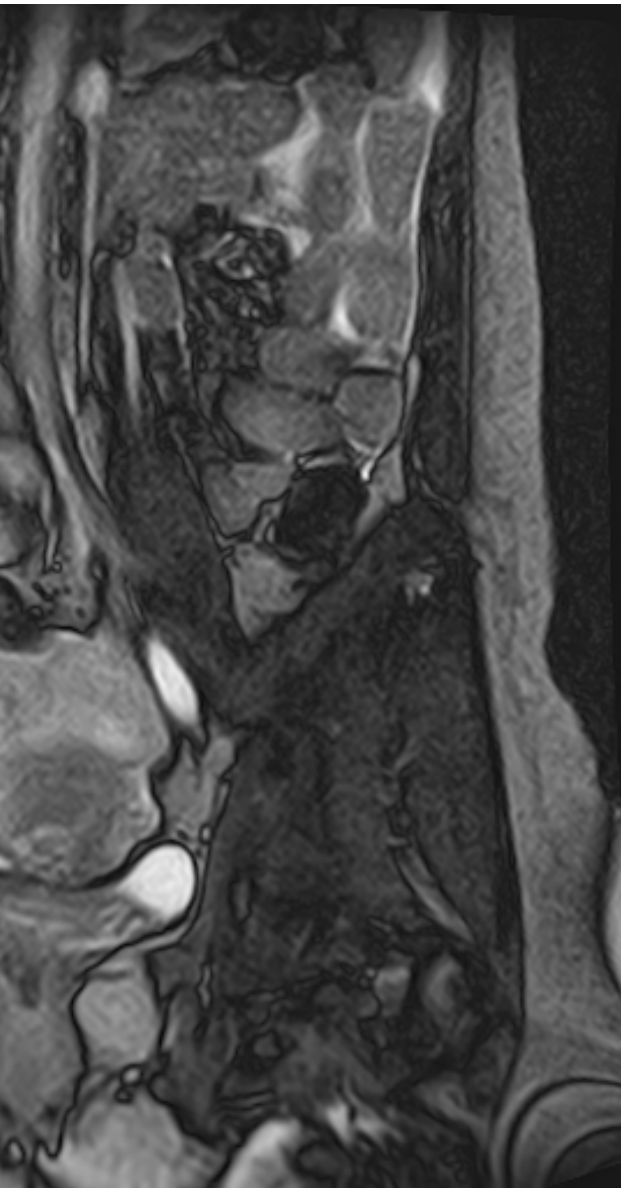
which confirmed the presence of both an intrauterine pregnancy and an ectopic pregnancy. The patient was transferred to an OSH for definitive management of heterotopic pregnancy with ruptured ectopic pregnancy.

*Discussion written by:*

**Grace Lagasse**  
**University of Cincinnati R1**

# 0 Second Rule

? You should probably just get it.



## discussion

## #lessonslearned

The patient presented with abdominal pain and vaginal bleeding in pregnancy with a confirmed IUP based on bedside transvaginal ultrasound. Her evolving abdominal exam led her practitioner to discover a heterotopic pregnancy with a ruptured ectopic pregnancy on advanced imaging.

Heterotopic pregnancy is the simultaneous existence of an intrauterine and an extrauterine, or ectopic, pregnancy. In natural pregnancies, which originate without the use of assisted reproductive technologies (ART), heterotopic pregnancies are very rare, and occur in 1 in 30,000 pregnancies. With ART, the incidence of heterotopic pregnancies is between 1 in 100 and 1 in 500 pregnancies.<sup>3,5</sup>

Risk factors for heterotopic pregnancy in a naturally conceived pregnancy are the same as those for ectopic pregnancies: tubal damage due to pelvic inflammatory disease, endometriosis or tubal surgery.<sup>4</sup> Heterotopic pregnancies are most often located in the fallopian tubes but can also implant in the cornual region, cervix, ovary, or on old cesarean scars. The median gestation at time of diagnosis for heterotopic pregnancy is between 6-9 weeks.<sup>3</sup> Patients with heterotopic pregnancy commonly present with abdominal pain, vaginal bleeding, or hemodynamic instability.

Heterotopic pregnancy is a diagnostic dilemma in women who have naturally conceived pregnancies because they have a confirmed intrauterine pregnancy on imaging that has the potential to modify future workup. In the emergency

department, the diagnosis of ectopic pregnancy is considered a diagnosis of exclusion, which precariously leaves the opportunity for a missed heterotopic pregnancy.<sup>2,3</sup> In patients with confirmed intrauterine pregnancies the diagnostic pathway for abdominal pain and or vaginal bleeding in the presence of a closed cervical os includes threatened abortion versus other acute abdominal pathology such as appendicitis, ovarian torsion, and heterotopic pregnancy.<sup>3,4</sup>

Heterotopic pregnancies are managed differently than ectopic pregnancies because of the co-existence of an intrauterine pregnancy. A ruptured ectopic pregnancy is treated with emergent surgical intervention by OBGYN. Often, the intrauterine pregnancy can be carried to term. If the ectopic pregnancy is not ruptured, the options for treatment expand depending on the mother's wishes regarding her intrauterine pregnancy.<sup>3</sup>

1 - American College of Emergency Physicians Policy Statement Emergency Ultrasound Guidelines." ACEP Policy Statement (2008).

2 - Krause, Richard S., et al. "Ectopic Pregnancy and Emergencies in the First 20 Weeks of Pregnancy." Tintinalli's Emergency Medicine: A Comprehensive Study Guide. Eds. Judith E. Tintinalli, et al. New York, NY: McGraw-Hill, 2011.

3 - Talbot, K. R. Simpson, N. Price, and S.R. Jackson. "Heterotopic Pregnancy." J Obstet Gynaecol Journal of Obstetrics & Gynaecology: 231-233.

4 - Umranikar, Sameer, Aarti Umranikar, Junaid Rafi, Pauline Bawden, Shalini Umranikar, Ben O' Sullivan, and Adam Moors. "Acute Presentation of a Heterotopic Pregnancy following Spontaneous Conception: A Case Report." Cases Journal: 9369.

5-Varras, Michael, Christodoulos Akrivis, Grigorios Hadjopoulos, and Nikolaso Antoniou. "Heterotopic Pregnancy in a Natural Conception Cycle Presenting with Tubal Rupture: A Case Report and Review of the Literature." European Journal of Obstetrics & Gynecology and Reproductive Biology: 79-82

## #lessonslearned

Although I was not initially suspicious for a heterotopic pregnancy, I maintained high clinical suspicion for an acute abdominal process as the etiology for the patient's persistent symptoms and pursued advanced imaging which led to the correct diagnosis. My #lessonlearned was to always pay attention to the "spidey sense" that accompanies certain patients. If you think there may be something else going on with a patient it is important to investigate further or observe them for a longer amount of time!





**Natalie Kreitzer, MD**  
**University of Cincinnati 2014**

*Dr. Kreitzer is a former resident editor and currently serves as a faculty editor for AOBP while doing her Neurocritical Care Fellowship at UCMC.*

## case

It was a busy R3 shift. We got a very elderly male in the SRU (in his late 80s), who had died in his bed. His wife was with him at the time and called EMS. He arrived to the ED in PEA arrest, and we coded him. There was nothing particularly unusual or striking about the code. We never got a pulse back and he died. His wife showed up a bit after this and was waiting in the social work office. I took care of a few things before I went back to talk to her, and was not as prompt as I should have been I think. She also looked like she was very elderly. When I talked to her, she was alone. She did not cry, scream, or do anything dramatic. She seemed very accepting of his death. I was only with her for a couple of minutes.

Later, I found out that she had asked or complained to the hospital about not being given enough or appropriate information about her husband's manner of death (even though we didn't really know why he died). I realized how abrupt I had been with her - and I had basically talked to her like I had a "script" of how to tell people bad news.

## discussion

Breaking bad news is unfortunately a common occurrence in the ED. Conversations that are difficult in the best of circumstances become even more challenging when they come as a surprise to patients and families, in a public and hectic setting, or outside a longstanding physician-patient relationship. As Dr. Kreitzer reflects, events that are routine to us may be the worst moments of another person's life, and it's important to give these the preparation, time and respect they deserve.

Sometimes it's obvious that we're about to rock someone's world, such as informing a fam-

ily about a death, or a patient their abdominal pain is cancer. Other moments are less dramatic on the surface, but deeply important to an individual. "It looks like you have an STT" might mean a spouse has been unfaithful; "your hip is broken," the end of functional independence. No single script or strategy can account for all such situations, but there are a few best practices to keep in mind.

### Breaking Bad News in the Pod

#### 1. Preparation

- Choose and use your space wisely. Close the door or curtain, and bring in a stool or chair so you can sit eye-to-eye with the patient.
- Eliminate distractions. Hand off phones and radios so you can give uninterrupted attention to your patient/family.
- Know the details. Some patients may ask about tumor size, lab values or other details while they process the news. Consider printing CT reports or other relevant information from EPIC and having it immediately available.
- Make the patient comfortable. Treat pain or nausea. If the bad news follows a pelvic exam, let the patient get dressed (or at least out of the lithotomy position) before you give the news.

#### 2. Set the Stage

- Ask the patient if they'd rather speak in private or wish to include family/visitors at the bedside in the conversation.
- If you're following up on results for a patient you got in sign out, make a quick visit to the room first to introduce yourself and establish a relationship. Return a few minutes later to discuss results.
- Find out what they already know - or suspect - about their medical condition and use this to frame the news.

#### 3. Be Clear

- Fire a warning shot: "I have some bad news"
- Use direct, concise language and avoid euphemisms (e.g. say the word "cancer" instead of "growth" or "mass").

#### 4. Respond to Emotions

- If unsure what to say, a few moments of silence may be most appropriate.

## #lessonslearned

### 5. Next Steps

- Inform the patient what the next steps will be in evaluation or treatment
- Be prepared to offer a range of possible prognosis. It's important to provide some hope, but not false hope. Your attitude in the first few moments can set the trajectory for how they view their illness for months to come.

### Death Notifications

Many of the above concepts apply to death notifications as well. Some additional points:

- Ask the social worker to clarify relationships before you start the conversation, so that you can direct your attention to the spouse or most appropriate next-of-kin.
- Establish what the family already knows about the situation. If they witnessed paramedics starting CPR, you can usually move quickly to saying the patient died. Otherwise you may need to briefly re-cap the course of the illness or accident. Avoid details of the resuscitation at this point.
- Clearly state "[Name] has died." Avoid euphemisms like "is gone" or "passed away."
- Be silent for a few moments; families are unlikely to hear anything you say in the moments after the initial notification anyway.
- If the family found the patient in distress, validate whatever actions they took to help their loved one - "You did everything you could have done."
- If appropriate, offer reassurance that the death was peaceful, quick or painless.
- Give a few moments for questions, and make sure you leave the family with a nurse or social worker to provide continued support.

*Discussion written by:*

**Chris Richardson, MD**  
**University of Cincinnati R2**

Steps of Success

1. Preparation
2. Set the Stage
3. Be Clear
4. Respond to Emotions
5. Next Steps

## #lessonslearned

The lesson I learned was that these moments are a very small piece of a busy shift to us, but that they are moments that patients and families carry with them for a very long time.

Continued From Page 5

receiving open-label norepinephrine (NE) and either vasopressin (0.01-0.03 units/min) or NE (5-15 mcg/min).<sup>9</sup> No difference was found between the vasopressin/NE and NE-alone groups regarding mortality (35.4% and 39.3%, respectively; p=0.26). The NE requirement was significantly lower in patients receiving vasopressin during the first four days (p <0.001). In a subgroup of less-severe septic shock (patients requiring NE <15mcg/min at randomization), mortality was lower in the vasopressin/NE group compared to the NE-alone group at 28 days (26.5% vs. 35.7%; p=0.05). The 2012 Surviving Sepsis Campaign (SSC) guideline recommends NE as the first-line vasopressor in septic shock (grade 1B), and concomitant vasopressin 0.03 units/min (non-titratable) to increase mean arterial pressure (MAP) or decrease NE requirement.<sup>10</sup> A small retrospective cohort study compared NE, vasopressin, and dopamine and found no difference in mortality.<sup>11</sup> However, no studies have assessed the safety of vasopressin as the first-line vasopressor in septic shock.<sup>1</sup> Thus, SSC does not recommend vasopressin be used as the single initial vasopressor.<sup>10</sup> Small randomized, controlled trials have compared increased doses of vasopressin (e.g., 0.06 units/min) to standard dose and found increased doses were associated with increased blood pressure and reduced NE requirement, along with increased rate of adverse effects (e.g., decreased intestinal mucosal perfusion, increased bilirubin, and increased serum

transaminases).<sup>1</sup> The SSC recommends that vasopressin doses greater than 0.03-0.04 units/minute be reserved for salvage therapy.<sup>10</sup>

Evidence regarding the use of vasopressin in other shock states is limited.<sup>12-14</sup> Initial therapies should attempt to address the underlying causes of the hemodynamic instability. Cardiogenic shock is associated with a less-significant reduction in endogenous vasopressin concentrations

“ Within the first six hours of sepsis and septic shock, endogenous vasopressin serum concentrations increase 20-fold to 200-fold compared to baseline ”

compared to septic shock.<sup>1</sup> However, a small, retrospective cardiogenic shock study indicated vasopressin had similar effects on blood pressure and increased urine output compared to norepinephrine.<sup>13</sup> A meta-analysis of hemorrhagic shock in animal studies comparing vasopressin or terlipressin (a synthetic analog of vasopressin) to other vasopressors or placebo found that vasopressin/terlipressin was associated with reduced mortality (15% vs 63%; p <0.001). However, a retrospective cohort of trauma patients

requiring vasopressors within 72 hours of presentation found vasopressin use was associated with increased mortality (51% vs 41%; p=0.002).<sup>15</sup> Vasopressin use in cardiogenic and hemorrhagic shock requires further evaluation in prospective human trails.

Vasopressin is an endogenous hormone which acts on multiple receptors and exerts a variety of clinical effects. Exogenous vasopressin's ability to induce potent vasoconstriction makes it an option to replace either the first or second dose of epinephrine in ACLS. Fixed-rate continuous infusion vasopressin can be used as an adjunct to first line vasopressors in septic shock primarily in an effort to improve volume retention. In cardiogenic and hemorrhagic shock, vasopressin has not been well-studied in humans, and future prospective studies are warranted.

- Russell JA. Bench-to-bedside review: vasopressin in the management of septic shock. *Critical Care* 2011;15:226.
- Holmes CL, Landry DW, Granton JT. Review: vasopressin and the cardiovascular system part 1 – receptor physiology. *Critical Care* 2013;7:427-434.
- Krismer AC, Dunser MW, Lindner KL, et al. Vasopressin during cardiopulmonary resuscitation and different shock states: a review of the literature. *Am J Cardiovasc Drugs* 2006;6:51-68.
- Morris DC, Dereczyk BE, Grzybowski M, et al. Vasopressin can increase coronary perfusion pressure during human cardiopulmonary resuscitation. *Acad Emerg Med* 1997;4:878-83.
- Neumar RW, Otto CW, Link MS, et al. Part 8: adult advanced cardiovascular life support. *Circulation* 2010;122:S729-67.
- Aung K, Htay T. Vasopressin for cardiac arrest: a systemic review and meta-analysis. *Arch Intern Med* 2005;165:17-24.
- Vasopressin. Lexi-Drugs. Lexicomp. Wolters Kluwer Health, Inc. Hudson, OH. Available at: <http://online.lexi.com>. Accessed May 13, 2014.
- Mentzelopoulos SD, Malachias S, Chamos C, et al. Vasopressin, steroids, and epinephrine and neurologically favorable survival after in-hospital cardiac arrest: a randomized clinical trial. *JAMA* 2012;310:270-9.
- Russell JA, Walley KR, Singer J, et al. Vasopressin versus norepinephrine infusion in patients with septic shock. *N Engl J Med* 2008;358:877-87.
- Dellinger RP, Levy MM, Rhodes A, et al. Surviving Sepsis Campaign: international guidelines for management of severe sepsis and septic shock: 2012. *Crit Care Med* 2013;41:580-637.
- Hall LG, Oyen LJ, Taner CB, et al. Fixed-dose vasopressin compared with titrated dobutamine and norepinephrine as initial vasopressor therapy for septic shock. *Pharmacotherapy* 2004;24:1002-12.
- Reynolds HR, Hochman JS. Cardiogenic shock current concepts and improving outcomes. *Circulation* 2008;117:686-97.
- Mann HJ, Nolan PE. Update on the management of cardiogenic shock. *Curr Opin Crit Care* 2006;12:431-6.
- Cossu AP, Mura P, De Giudici LM, et al. Vasopressin in hemorrhagic shock: a systemic review and meta-analysis of randomized animal trials. *BioMed Research Intl* 2014;doi:10.1155/2014/421291.
- Collier B, Dossett L, Mann MM, et al. Vasopressin use is associated with death in acute trauma patients with shock. *J Crit Care* 2010;25:173.e9-14.

|                                   |  |
|-----------------------------------|--|
| Vasopressin Use per Disease State | <b>Cardiopulmonary resuscitation (ACLS)</b>  |
|                                   | 40 units IV/IO in replacement of either the first or second dose of epinephrine <sup>5</sup>   |
|                                   | <b>Septic Shock</b>  |
|                                   | Fixed-rate vasopressin can be added to norepinephrine to raise MAP or decrease NE dosage<br>Not to be used as single initial vasopressor<br>Doses >0.03-0.04 units/minute are to be reserved for salvage therapy <sup>10</sup> |
|                                   | <b>Cardiogenic Shock</b>   |
|                                   | Limited Evidence Supporting Use <sup>13</sup><br>Limited Evidence Supporting Use <sup>3,14</sup>   |

Table 2

# BEWARE: Aortic Dissections in B-pod

case one

## History of Present Illness

The patient is a male in his mid-30s with a past medical history significant for hypertension who presented via EMS with pain all over, anxiety and shortness of breath. The EMTs reported that he had smoked marijuana about 30 minutes before his presentation from his normal supply. At the scene he was noted to be very agitated, diaphoretic and vocal about his pain. He was yelling that he was hurting all over, he was having trouble breathing, and that he wanted to be sedated. He states that he has never had problems like this in the past.

## Review Of Systems

+chest pain, +abdominal pain, +back pain, +myalgias, +neck pain, +tingling, +headaches, -fevers, -shortness of breath

## Physical Exam

|            |        |           |
|------------|--------|-----------|
| Temp       |        | O2 Sat    |
| 97.7       | BP     | 100%      |
| Heart Rate | 189/83 | Resp Rate |
| 75         |        | 30        |

Constitutional: He appears well-developed and well-nourished.  
 HENT: Unremarkable  
 Eyes: Conjunctivae and EOM are normal. Pupils are equal, round, and reactive to light.  
 Neck: Normal range of motion. Neck supple.  
 Cardiovascular: Normal rate, regular rhythm, normal heart sounds and intact distal pulses.  
 Pulmonary/Chest: Effort normal and breath sounds normal. No respiratory distress. He has no wheezes. He has no rales.  
 Abdominal: Soft. Bowel sounds are normal. He exhibits no distension. There is no tenderness.  
 Musculoskeletal: Normal range of motion. He exhibits no edema and no tenderness.  
 Lymphadenopathy: He has no cervical adenopathy.  
 Neurological: He is oriented to person, place, time and situation. Normal speech without aphasia or dysarthria. Moves all extremities spontaneously and symmetrically. Gait is not tested.  
 Skin: He is diaphoretic.  
 Psychiatric: His mood appears anxious. His affect is labile. He is agitated.

## Work-up

CBC, BMP, LFTs, lipase,  
 UA all unremarkable

## EKG

Rate 60, normal sinus rhythm, no  
 acute changes from prior

## Past Medical History

Hypertension

## Past Surgical History

None

## Medications

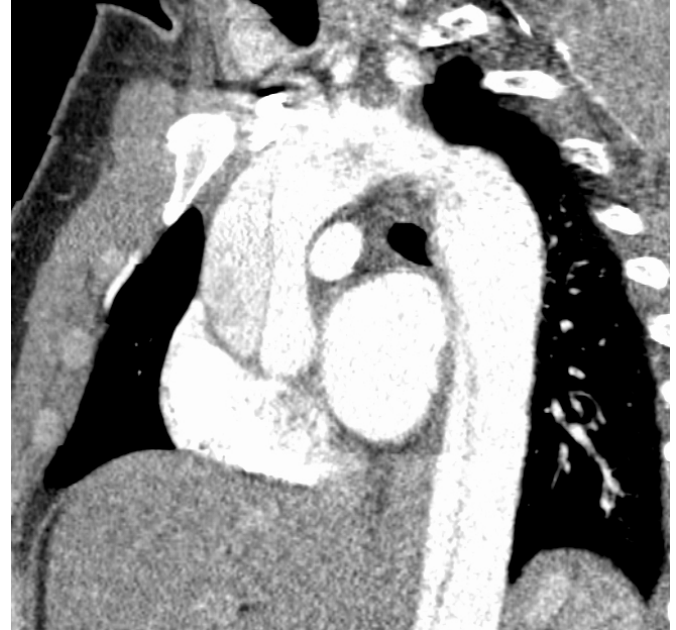None

## Allergies

None

## Social History

Daily THC use, 1/5 ppd  
 smoker, social drinker



Case One: CT Chest: Large type A dissection extending from the aortic root near the origin of the right coronary artery to the descending thoracic aorta with the inferior extent of the dissection not imaged. The dissection flap likely involves the origin of the left subclavian artery but does not extend distally in the artery.

## ED + Hospital Course

The patient arrived complaining of severe diffuse pain. The initial assessment revealed a well-dressed, well-nourished male in acute distress, flailing in bed, unable to assume a comfortable position. He reported pain in his neck, abdomen, and right leg. Although his strength was normal, the pain in his right leg was so severe that he was unable to bear weight causing him to nearly fall on the nurse in the bathroom. Patient was markedly hypertensive and intermittently bradycardic but the remainder of his vitals were within normal limits.


The blood work obtained initially was unremarkable. The team addressed his pain and agitation with hydromorphone and lorazepam at first. The patient, however, continued to complain of abdominal pain. Subsequently, a CT abdomen/pelvis with IV and PO contrast was ordered which revealed his aortic dissection. A completion CT scan of the chest demonstrated a Type A aortic dissection extending from his right coronary artery to the right common iliac artery.

The patient was immediately moved to the SRU and an esmolol drip was started for his SBP >200. He became bradycardic with the B-blocker, so nicardipine was added as a second blood pressure control agent. Vascular surgery and cardiothoracic surgery were both consulted and evaluated the patient at bedside. They requested a cardiology consult for further blood pressure control. Car-



diology recommended IV hydralazine PRN. The patient was then taken to the OR with cardiac surgery for repair of ascending aortic dissection with a graft. The surgery was successful and he was extubated on POD 1 without complications.

His type B dissection was not repaired acutely but was closely monitored by Vascular Surgery. His post-operative hospital course was complicated by persistent hypertension requiring multiple medications to keep his SBP <130. His right lower extremity had claudication symptoms with activity initially but was perfused at rest. He had +1 pulse in his right leg without claudication symptoms at discharge and he will follow up with vascular surgery as an outpatient for possible elective endovascular repair of his Type B dissection.



**Kyle Walsh, MD**  
University of Cincinnati 2015

*Dr. Walsh recently graduated from residency and is starting a Neurocritical Care Fellowship at UCMC.*

## #lessonslearned

Re-evaluate your patients, especially the ones that may get under your skin and the patients whose pain you finally got under control. A more specific history once the patient had calmed down may have led to a quicker diagnosis.  
-Dr. Walsh

### case two

The patient was a male in his mid-40s who presented with the chief complaint of “unable to walk”. He also complained of vague, intense back pain that started the day before presentation. On exam he was found to have normal vitals with flaccid bilateral lower extremities. The team’s top differential diagnoses were spinal cord lesion versus aortic dissection.

The decision was made to obtain an MRI for spinal cord lesion. The MRI took several hours to complete and when he returned to B pod he quickly decompensated and went into PEA arrest. The patient was immediately

moved to the SRU and ACLS was initiated. Approximately 10 minutes into the code, radiology called to report an acute aortic dissection was picked up on the MRI. The patient was coded for >30min without return



**Justin Benoit, MD**  
University of Cincinnati 2014

*Dr. Benoit served as an attending at UCMC immediately after graduating and is currently starting his EMS fellowship at UCMC*

## #lessonslearned

Always rule out the most time sensitive and immediately life threatening pathology first.  
- Dr. Benoit

### discussion

of spontaneous circulation.

Both Dr. Walsh’s and Dr. Benoit’s patients presented to B-pod complaining of something other than chest pain, had abnormal but stable vital signs initially, and had aortic dissections diagnosed incidentally. Even though aortic dissections are the most common aortic pathology requiring acute surgical intervention, 38% of people who present with this pathology will be missed initially.<sup>1,2</sup> The incidence of aortic dissections has been reported to be between 2.3 and 4.6 per 100,000 people per year.<sup>2</sup> What makes this disease process even more terrifying is that 22% of patients go undiagnosed until an autopsy is performed.<sup>2</sup> Mortality in patients who go without treatment is 25% in the first 24h and 75% within 2 weeks of the initial dissection.<sup>2</sup> However, patients who receive proper treatment have a greater than 90% survival rate at 1 year.<sup>2</sup> As evidenced by this data, timely diagnosis and treatment of aortic dissection, much like stroke and myocardial infarction, is essential.

Aortic dissections occur when a tear in the intimal lining of the vessel allows blood from the lumen to seep into the wall of the vessel causing a separation of the intima and the media. Propagation of this process can lead to vessel occlusion, embolic phenomena, and vessel rupture. There are 2 systems of classification: the Stanford Classifications and the DeBakey Classification (see Figure 1). In the Stanford Classification system, dissections

are categorized as either Type A or Type B. Type A dissections are defined as those involving the ascending aorta and Stanford Type B dissections are defined as those that start distal to the origin of the subclavian artery. The DeBakey Classification system categorizes dissections into 3 types: Type 1 dissections involve the ascending aorta, aortic arch, and descending aorta; Type 2 involve the ascending aorta; and Type 3 involve the descending aorta. The Stanford classification is the more commonly used system. The patient in Dr. Walsh’s case is an example of a Stanford Type A/DeBakey Type 1 because of the ascending aortic involvement. Of note, 60% of dissections involve the ascending aorta.<sup>2</sup>

Aortic dissections classically present with tearing or ripping pain that radiates to the back. However, a description of tearing pain is only 38% sensitive for an acute dissection.<sup>9</sup> The most sensitive complaints were any complaint of pain (90%), severe pain (90%), and sudden onset pain (84%).<sup>3</sup> Patients typically present with hypertension, which is most prominent in those with Type B dissections, and usually have pain that is difficult to control, as in Dr. Walsh’s case. No single physical exam finding is sensitive for dissection. Pulse differences and aortic regurgitation murmurs are only present in 19% and 44% of Type A dissections, respectively.<sup>3</sup> These physical exam findings are even less sensitive in Type B dissections.<sup>3</sup> Type A dissections present with stroke like symptoms 20% of the time due to involvement of the carotids.<sup>4</sup>

Most lab markers of acute dissection are non-specific, and the few that show potential are not readily available in most hospitals. D-dimer is the most widely studied marker and may have a place in the diagnosis of dissection. A meta-analysis of d-dimers in acute dissections showed a sensitivity of d-dimer for acute dissection using a cutoff of <500ng/ml is 97% and the negative predictive value is 96%.<sup>5</sup> However, there are older studies showing false negative rates up to 18%.<sup>6</sup> Furthermore, d-dimer cannot screen for intramural hematomas, a subset of aortic dissections in which a hematoma forms within the vessel wall but does not communicate with the lumen. Intramural hematomas are treated with the same urgency as classic dissections. For these reasons d-dimer is not currently recommended as a screening tool for ruling out aortic dissections. Chest x-ray is a good screening tool, as approximately 80% of dissections will

Continued on page 14

**Aortic Dissections**  
Continued from page 13

should not be used to rule out dissection for a patient in which there is a high index of suspicion. Ultimately, given the high mortality of a missed aortic dissection, there should be a low threshold to obtain definitive imaging. CT angiogram is the most commonly used diagnostic tool in the emergency department due to availability. However, both MRA and TEE are considered to be adequate at identifying dissections.<sup>3</sup>

show a widened mediastinum.<sup>3</sup> However, this

Often, as in Dr. Walsh's case, more than one blood pressure agent is required to obtain the goal blood pressure. It is imperative to have B-blockers on board prior to adding additional antihypertensives to prevent rebound tachycardia. Ideally, the patient's systolic blood pressure should be under 120mmHg-100mmHg but it can be titrated lower as long as the patient's mental status is maintained. The goal heart rate should be under 60 bpm.<sup>3</sup> B-blockers are the only medical intervention in acute aortic dissection to show an improvement in mortality.<sup>6</sup>

on the location and extent of the dissection at the time of presentation. It is important to remember that there are many historical features, physical exam findings, and screening tests that should heighten the clinician's suspicion for aortic dissection and prompt the clinician to obtain a definitive test. However, there is no one screening test that can rule out an aortic dissection and the morbidity and mortality of missing this disease process is extremely high. With prompt diagnosis, medical management, and, when appropriate, definitive surgical repair these patients tend to do well overall. In order to do all of the above in an environment such as B-pod, one must have a high clinical index of suspicion and a low threshold to obtain the definitive study in a timely manner.

**#lessonslearned**

Keep your index of suspicion high, especially in the setting of objective evidence of pathology such as hypertension and diaphoresis.  
-Dr. Walsh

Management of any aortic dissection acutely is focused on decreasing shear forces on the wall of the aorta by lowering both blood pressure and heart rate. B-blockers are the ideal first agent because they address both blood pressure and heart rate. Esmolol is the first line beta-blocker as it is easily titrated.

Patients with type A dissections have a 1- week mortality of 50% when managed medically.<sup>7</sup> However, when rapid surgical intervention is used to treat Type A dissections, mortality at one week decreases to 10-35%.<sup>8</sup> The patient in Dr. Walsh's case went directly from the emergency department to the operating room for surgical repair. Type B dissections tend to better overall, with an in-hospital mortality of around 10%. Indications for surgical repair of type B dissections include cases that present with end-organ dysfunction such as mesenteric ischemia, renal ischemia or limb ischemia. These complicated type B dissections traditionally have a higher mortality, between 25-50%, typically attributed to the extent of dissection and not surgery itself.<sup>3</sup> Endovascular repair is currently the surgical intervention of choice. Recent studies show that surgery may improve mortality of these patients to 11%, which is comparable to that of patients who are managed medically.<sup>2,8</sup>

It is not hard to see why patients who have aortic dissections leave an imprint on their provider's minds. These patients can present with a variety of chief complaints from leg pain to syncope to abdominal pain. They can appear sick or relatively well depending

**#lessonslearned**

Be aware of emotions that make you shy away from the patient's room. Once you are aware of them, you can control them and pursue the patient's complaint instead of just being relieved you finally succeeded in making them stop  
- Dr. Walsh

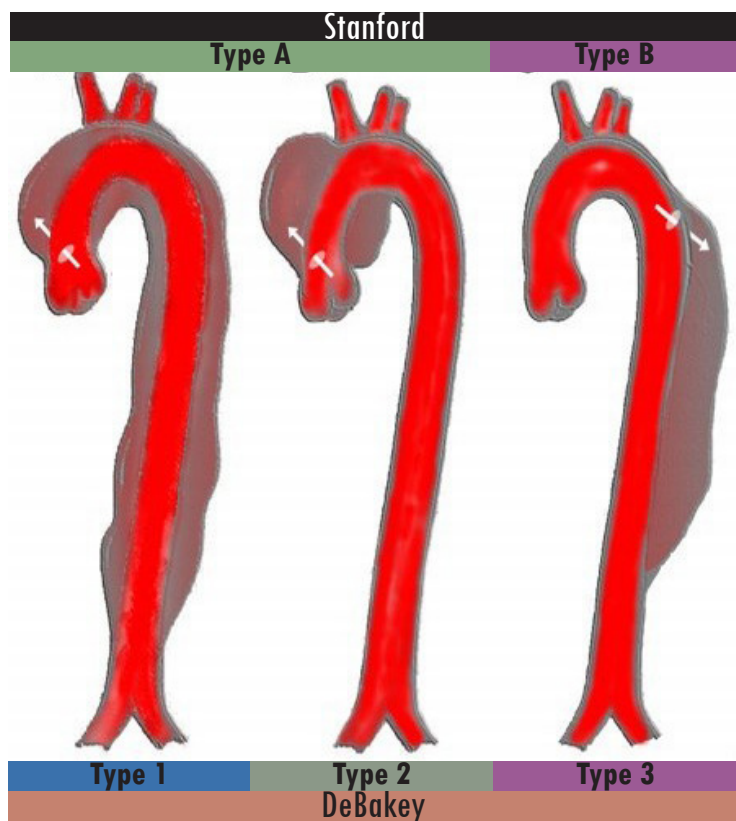


Figure 1: Classifications of Aortic Dissections<sup>10</sup>

- Hagan PG, et al. The International Registry of Acute Aortic Dissection (IRAD): new insights into an old disease. JAMA. 2000 Feb 16;283(7):897-903.
- Tekwani K, Chandra P; Emergency Medicine Reports: Aortic Dissection. EM Reports. 2012 Oct 8;33(22):258-267
- Braverman AC; Clinician Update: Acute Aortic Dissection; Circulation. 2010; 122: 184-188
- Conzelmann LO, Hoffmann I, Blettnet M, et al: Analysis of risk factors for neurological dysfunction in patients with acute aortic dissection type A: data from the German Registry for Acute Aortic Dissection Type A (GERAADA). Eur J Cardiothorac Surg 42: 557, 2012
- Shimony A, Filion KB, Mottillo S, et al: Meta-analysis of usefulness of D-dimer to diagnose acute aortic dissection. Am J Cardiol 107: 1227, 2011.
- Paparella D, Giorgio P, Scarscia G, et al: D-dimers are not always elevated in patients with acute aortic dissection. J Cardiovasc Med 10: 212, 2009.
- Nordon JM, Hinchliffe RJ, Loftus JM, et al: Management of acute aortic syndrome and chronic aortic dissection. Cardiovasc Intervent Radiol 34: 980, 2011.
- Nienaber CA, Powell JT: Management of acute aortic syndromes. Eur Heart J 33: 26, 2012.
- Klompas M. Does this patient have an acute thoracic aortic dissection? JAMA. 2002 May 1;287(17):2262-72. PubMed PMID: 11980527.
- http://commons.wikimedia.org/wiki/File:Aortic\_dissection\_class.jpg

Discussion written by:

Riley Grosso, MD  
University of Cincinnati R2

Now you know...  
Continued From Page 2

of the law describe any individual who “comes to the emergency department”. That’s easily applicable if someone walks in to your physical emergency department space, but what about a bystander who collapses 100 feet outside the emergency department door?

Furthermore, what does “stabilize” mean? To stabilize many medical conditions is a process that can take days or weeks. These questions, and others, have led to much subsequent case law sorting out the ramifications of the EMTALA. Further critique of the law stems from its passage as an unfunded mandate. That is, with EMTALA the government burdened hospitals, some operating at the margins, to care for patients they will not be reimbursed for, and may not have the resources to care for.

Because of such concerns, physicians lobbying for the law were initially skeptical of EMTALA, claiming that enforcement and effectiveness would be “crippled” by its vague descriptions and lack of funding. Initial concerns notwithstanding, 30 years later there is no doubting the impact that EMTALA has had on emergency care in the United States. For with EMTALA, Emergency Medicine put a legal stamp on its place in the broader medical community as the specialty that will care for every patient, anywhere, regardless of ability to pay.  
Now you know.

1. Proc (Bayl Univ Med Cent). 2001; 14(4): 339-346
2. EMTALA Statute <http://www.medlaw.com/statute.htm>. Accessed June 4, 2015.

*Have a public health or medical policy topic you have always wanted to know more about? Email us at [annalseditors@gmail.com](mailto:annalseditors@gmail.com) with suggestions.*

Respect Your aVR  
Continued from page 3

## discussion

The patient presented with chest pain, mildly elevated troponin, and isolated ST segment elevation in lead aVR with diffuse ST depressions throughout the other leads. Typically, isolated ST elevation is not an indication for emergent catheterization in an otherwise stable patient; however aVR may be the exception to that rule. aVR is a controversial lead when approaching EKG interpretation and decisions regarding acute management differ. Some physicians overlook changes in aVR, writing them off as reciprocal changes and nothing more. However, some physicians believe that isolated elevation in aVR is indicative of severe left main coronary artery disease and state that these patients should be treated as a STEMI and therefore require emergent revascularization.

The belief that ST elevation in aVR is indicative of severe left main coronary artery disease originated with several small studies. These studies showed specificities as high as 98% for left main coronary artery disease when aVR elevation is coupled with elevation in aVL.<sup>1</sup> They also showed a significant mortality difference between patients with troponin elevations with aVR elevation and patients with troponin elevations without aVR elevation, with mortality at 19.4% and 1.3% respectively.<sup>2</sup> However, these studies were very small with mostly non-emergency department patients.

Larger studies with a more appropriate patient population for extrapolation to the Emergency Department have shown that isolated elevation in aVR is associated with left main coronary artery disease in 14.7% of

patients. Patients with acute coronary syndrome (ACS) that do not have aVR elevation have left main coronary artery disease 5.1% of the time. In this same study, aVR elevation was also associated with increased mortality, though this increase was much less impressive (7.9 % vs 4.2%). Additionally, this mortality change was not significant when a multivariate analysis was performed. These studies indicated that aVR elevation is associated with many other risk factors that could

“...elevation in aVR should increase suspicion for clinically significant disease that will require an intervention beyond pure medical management.”

account for the increased mortality in this patient population. These patients are more likely to have the presence of ST depressions on their EKG, to be of older age, to have a higher heart rate, a higher GRACE risk score (estimates 6 month mortality in ACS) and worse Killip class (estimates 30 day mortality in ACS).<sup>3</sup> So even if isolated elevation in aVR does not warrant immediate intervention, it should increase a clinician’s concern for left main coronary artery disease. For patients presenting with the correct story and risk factors, elevated ST segment in aVR warrants a call to an interventional cardiologist immediately to ensure the occluded left coronary artery, or in our patient, the left circumflex

artery, can be appropriately managed.

Diffuse three vessel disease involving the left anterior descending, circumflex, and right coronary arteries is the typical indication for coronary artery bypass grafting. ST elevation in aVR carries a 55.9% association with either left main or three vessel disease as a combined outcome. Thus, elevation in aVR should increase suspicion for clinically significant disease that will require an intervention beyond purely medical management.

Management decisions regarding ST elevation in aVR remain variable. Those who follow the earlier literature (highly specific for left main disease, almost three fold increased mortality) recommend treating elevation in aVR with evidence of ischemia in other leads (e.g. diffuse ST depressions throughout) as a STEMI requiring emergent coronary artery catheterization.<sup>4</sup> Others who focus on the results of the newer studies recommend urgent but not emergent coronary artery catheterization (i.e. you don’t need to wake the cardiologist up at 3 AM) as long as the patients are responding appropriately to medical therapy.<sup>5</sup> Practically, the decision on which treatment strategy to pursue in practice depends on patient presentation, response to therapy, and clinician discretion.

1 - Kurisu S, Inoue I, Kawagoe T et al. Electrocardiographic features in patients with acute myocardial infarction associated with left main coronary artery occlusion. *Heart* 2004;90:1059-1060.

2 - Barrabes JA, Figueras J, Moure C, Cortadellas J, Soler-Soler J. Prognostic value of lead aVR in patients with a first non-ST-segment elevation acute myocardial infarction. *Circulation* 2003;108:814-819.

3 - Yan AT, Yan RT, Kennelly BM et al. Relationship of ST elevation in lead aVR with angiographic findings and outcome in non-ST elevation acute coronary syndromes. *Am Heart J* 2007;154:71-78.

4 - Nickson C. Life in the Fastlane: Cardiac Megacode- Cardiovascular Curveball 003. 2015.

Ref Type: Online Source

5 - Allely P. Life in the Fastlane: Another Widow Maker. 2015.

Ref Type: Online Source

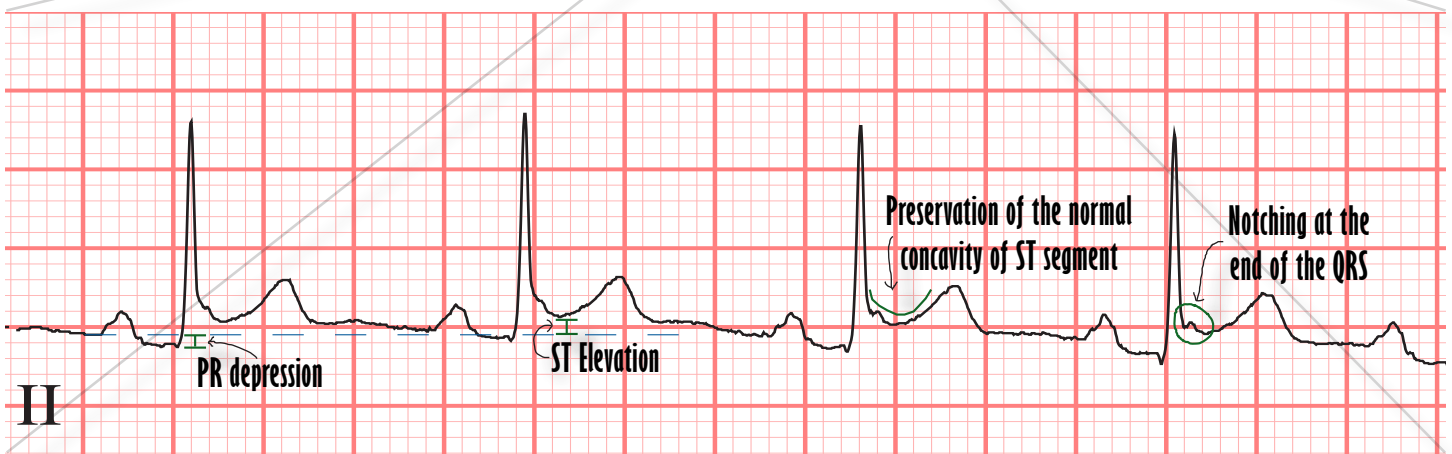
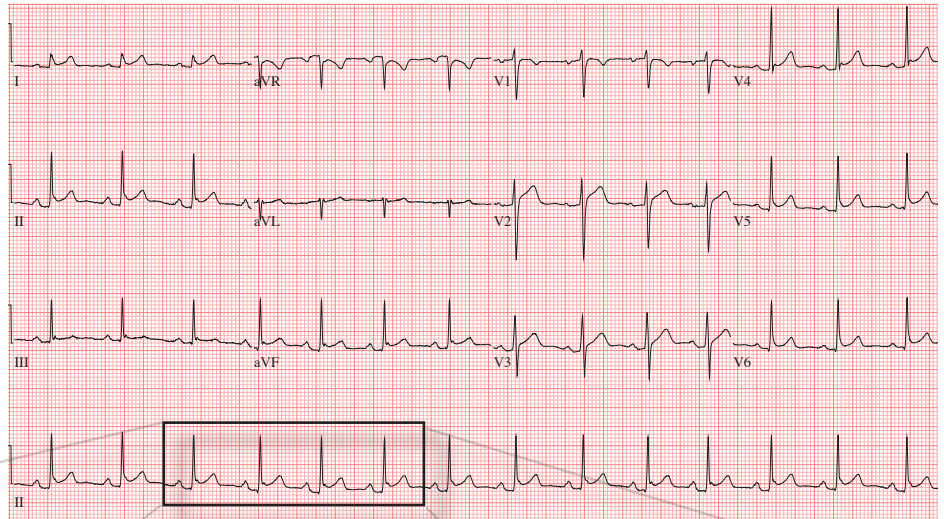


# EKG focus

## Pericarditis

Grace Lagasse, MD  
University of Cincinnati R1

Patient is a female in her late twenties with rheumatoid arthritis who presents complaining of chest pain that is pleuritic and improved by sitting forward.



### Pericarditis Diagnostic Criteria (Need 2 of 4)

1. Chest pain that is sharp and pleuritic, improved by sitting up or leaning forward, may radiate to trapezius ridge
2. Pericardial friction rub
3. EKG changes
4. Pericardial effusion

### Etiologies of Pericarditis

1. Infectious: viral and tubercular infections
2. Autoimmune: collagen vascular diseases
3. Metabolic: uremia
4. Post traumatic
5. Neoplastic: metastatic tumors

EKG & Case referred by: **Bret Betz, MD**  
University of Cincinnati R3

1. Imazio, M., and F. Gaita. "Diagnosis and Treatment of Pericarditis." Heart (2015).
2. Mahler, Simon A. "Chest Pain." Tintinalli's Emergency Medicine: A Comprehensive Study Guide. Eds. Judith E. Tintinalli, et al. New York, NY: McGraw-Hill, 2011. n. pag. AccessEmergency Medicine. Web. 1 Jun.2015. <<http://accessemergencymedicine.mhmedical.com/content.aspx?bookid=693&Sectionid=54783800>>.
3. Soloman, Caren G., and Martin M. Lewinter. "Acute Pericarditis." New England Journal of Medicine (2014): 2410-416.

## List of Submitted B Pod Cases

|                          | R4       | R1     |
|--------------------------|----------|--------|
| Clitoral Abscess         | Redmond  | Shah   |
| Transverse Myelitis      | Bohankse |        |
| GBS                      | Stull    | Yeager |
| Toxic Mushroom Ingestion | Redmond  | Miller |
| Abdominal Free Air       | Redmond  | Gorder |
| Submassive PE            | Stull    | Wilson |
| ST Elevation aVR         | Redmond  | Plash  |
| Myxedema Coma            |          |        |
| Aortic Dissection        | Walsh    | Edward |

Annals of B Pod is looking for YOU to submit your interesting cases of B Pod - There is a composition book at the R4 desk - please make sure to include the R1/R4 involved in the case, a brief synopsis and a patient sticker  
[annalseditors@gmail.com](mailto:annalseditors@gmail.com)